

# IMPLANT REPLACEMENT OF A FRACTURED INCISOR

## MANAGEMENT OF A COMPLEX ESTHETIC SITUATION USING CAMLOG® SCREW-LINE IMPLANTS

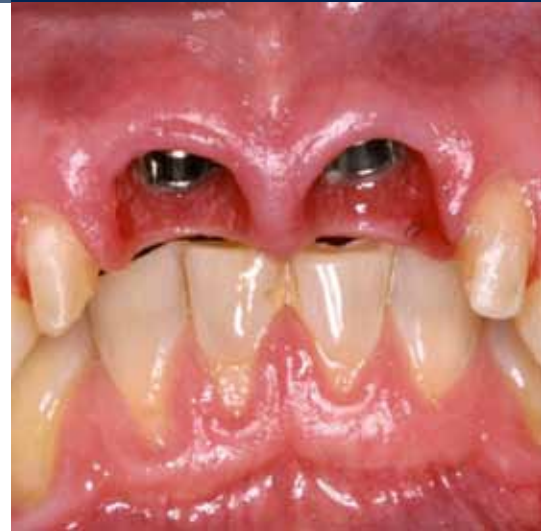a perfect fit™



Dr. Peter Hunt  
Philadelphia, USA

Peter Hunt is a fourth generation dentist originally from Great Britain. After training at Guy's Hospital in Great Britain and Residencies in Maxillo-Facial Surgery, he obtained a Master's Degree in Advanced Restorative Dentistry at the Eastman in London. He then received advanced training in Periodontics and Periodontal Prosthesis from the University of Pennsylvania, USA. He later became a Clinical Professor of Periodontics at Penn and later still a Professor of Restorative Dentistry, Post Graduate Director and Director of Implantology and Periodontal Prosthesis at NSU in Florida.

Peter has used Camlog for more than a decade and has lectured around the world at Camlog meetings. He was Program Director for the Camlog USA Congress in June 2009. He's a Member of Camlog's International Council of Experts and is the Editor of camlogconnect.com. His practice of Implant and Rehabilitation Dentistry is located in Philadelphia, USA.



### USED IMPLANTS

Tooth	18	17	16	15	14	13	12	11	21	22	23	24	25	26	27	28
Implant type								SL	SL							
Implant length								13.0	13.0							
Implant Ø								5.0	5.0							
Implant surface								P	P							

Tooth	48	47	46	45	44	43	42	41	31	32	33	34	35	36	37	38
Implant type																
Implant length																
Implant Ø																
Implant surface																

Implant type: ROOT-LINE (RL)/SCREW-LINE (SL) Implant surface: Promote® (P)/Promote® Plus (PP)

### PROSTHODONTICS

- standard
  - platform switching
  - removable
  - fixed
  - crown
  - bridge
  - cemented
  - screw-retained
  - partial denture
  - full denture
  - others
- 
- Universal Abutment
  - Esthomic® Abutment
  - Telescope Abutment
  - Gold-plastic Abutment
  - Ceramic Abutment
  - Custom Zirconia on Titanium Base
  - Logfit® Abutment
  - Locator® Abutment
  - Bar Abutment
  - Ball Abutment
  - others

## INFORMATION ABOUT THE PATIENT AND THE TREATMENT

The patient a healthy, 44 year old male, was concerned when his right maxillary central incisor became loose and slightly extruded. On examination it became apparent that the tooth was fractured. The esthetics of the region were compromised, with the clinical crown length of the central incisors being excessive. The alveolar housing appeared thin and there was concern that the labial bone in the region might have dehiscences and fenestrations. An Angle's Class II Division 1 malocclusion with an anterior deep bite was present.

Traditional modes of tooth replacement were discussed with the patient. All involved suspending a replacement crown over a resorbing ridge. While this might be able to supply a reasonable esthetic solution at the outset, the

esthetics would become worse with increasing resorption. For this reason, discussion turned to implant based solutions.

There was not much point in placing a single implant and attempting to match the gingival level around the implant to that of the adjacent central incisor. While "long crowns" can often be overcome by eruption therapy, the vertical fracture of the one incisor meant that the prognosis for eruption therapy in this particular case would be poor. So replacement of both central incisors by implants supporting crowns was the therapy selected. Augmenting the vertical ridge height at the time of implant placement was desirable. It was also decided to enhance the cosmetic result by crowning and increasing the size of the lateral incisors.

### Initial presentation

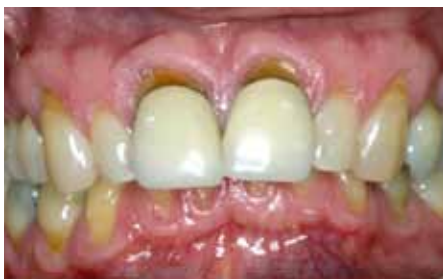

Fig. 1: Original view. The right central incisor is mobile and slightly extruded.

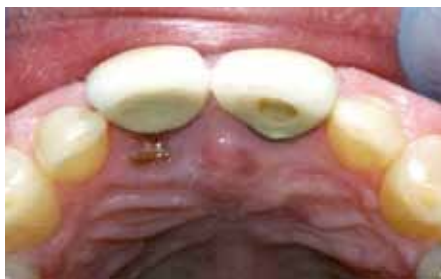

Fig. 2: Palatal view, which shows the evident fracture of the supporting tooth.

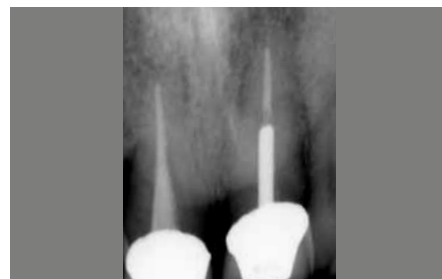

Fig. 3: Initial radiograph. Notice that the adjacent central incisor has endodontic and post therapy.

### Therapeutic considerations

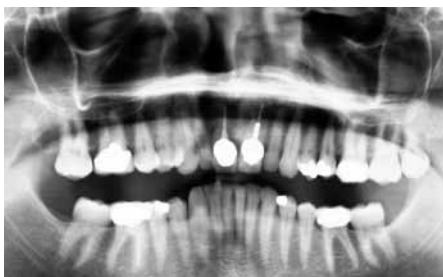

Fig. 4: Panorex showing the intact dentition and generally good supporting structures.

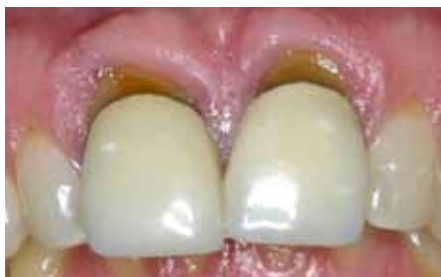

Fig. 5: Close-up view of the central incisors showing the excessively long clinical crowns.

The right central incisor was hopeless and needed to be extracted quickly. Three management protocols to avoid a resorbed ridge were available. First was socket regeneration. Second was to allow the ridge to heal after extraction, with later reconstruction of the resorbed ridge and later still implant placement. Third was immediate implant placement with augmentation. The choice comes at the time of extraction.

### Interceptive therapy

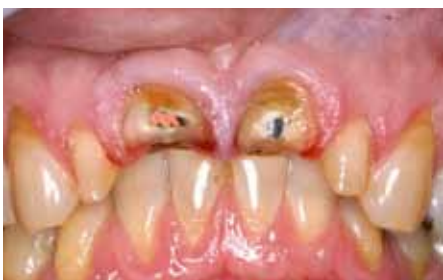

Fig. 6: The two central incisors were sectioned off at gum level and the lateral incisors were prepared for crowns. This ensured a clean operating field while fitting the provisional restoration.

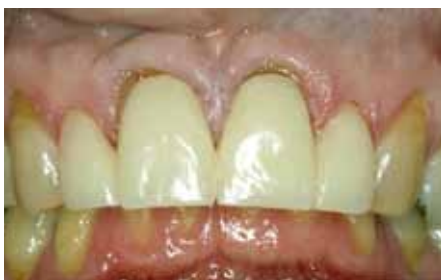

Fig. 7: The provisional bridge also serves as a surgical stent. It shows the location of the gingival margins at the start of the procedure which is useful if these are to be moved.

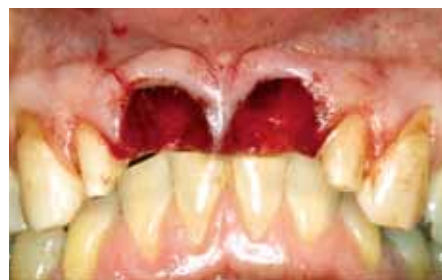

Fig. 8: The roots of the two central incisors have now been removed and the bone sockets curetted and inspected. The sockets are intact though very wide (8 mm).

## Implant placement

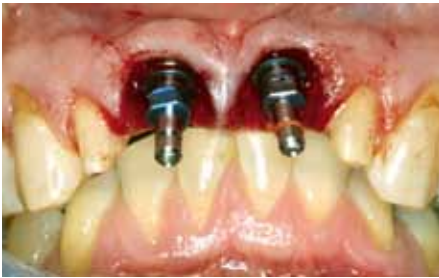

Fig. 9: 5.0x13.0mm J-Series SCREW-LINE implants have been placed to the palatal aspect of the sockets. The platforms were placed only slightly sub-gingivally.

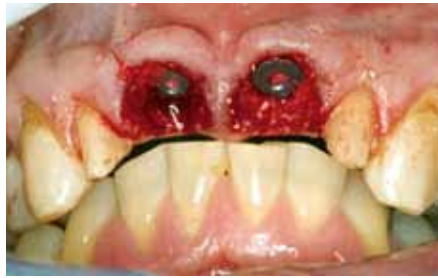

Fig. 10: The channel deficiencies about the implant were filled with Geistlich Bio-Oss® particles.

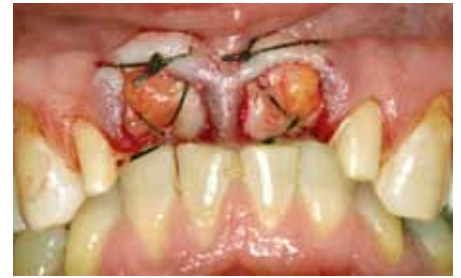

Fig. 11: The marginal gingiva was mobilized and advanced crestally. A connective tissue graft from the palate was placed over the implant platforms and down under the marginal gingiva.

## Healing with provisionals

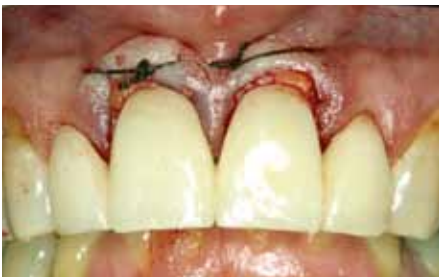

Fig. 12: The previously fabricated provisional was test fitted. The labial margins impinged on the soft tissues, which could be expected to swell in the early post-operative phase.

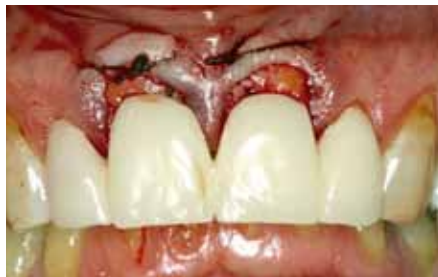

Fig. 13: The labial margins were shortened at the gingival, which improved the esthetics.

While there is much discussion about ensuring correct mesiodistal and buccolingual placement for an implant, the correct vertical position of the implant platform is critical for ensuring adequate soft tissue coverage and developing the optimal emergence profile. In this case, soft tissue augmentation over the implant platforms was critical to achieve the desired result.

## Post-operative healing

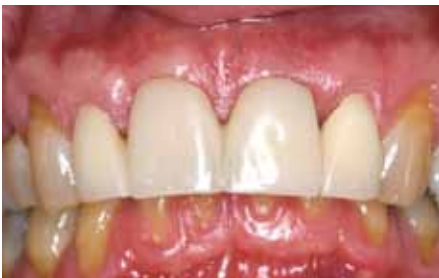

Fig. 14: The provisional restoration functioned well for the healing period of three months.

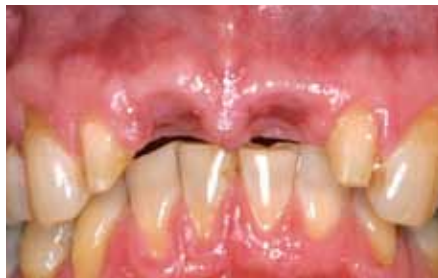

Fig. 15: On removal, the implant platforms were covered with gingiva and peaks of soft tissue remained in the potential embrasure regions.

Emergence profile development is where the soft tissues covering the implant platform are reshaped so they appear as though a tooth is emerging from the gingival complex.

In Fig. 17 it can be seen that the provisional restoration has squeezed the rounded and slumped papillae back into peaks. This needs to be replicated in the final abutment.

## Emergence profile development

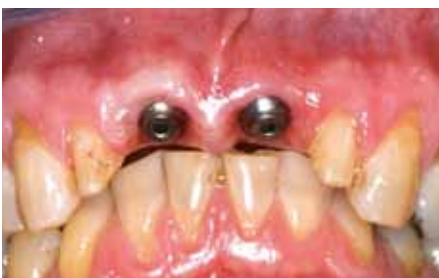

Fig. 16: Trans-gingival gingivaformers were placed through minor access incisions. Implant level impressions were made at the same session.

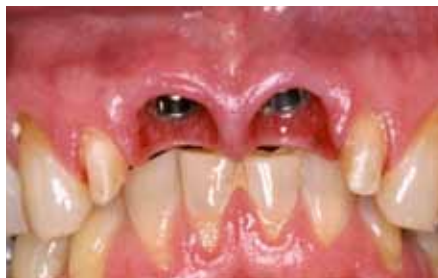

Fig. 17: Screw-retained provisional restorations developed the desired soft tissue "Emergence Profile" and re-established natural form papillae.

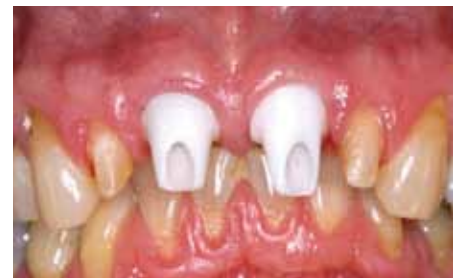

Fig. 18: The ceramic abutment posts maintain the established subgingival form.

## Before

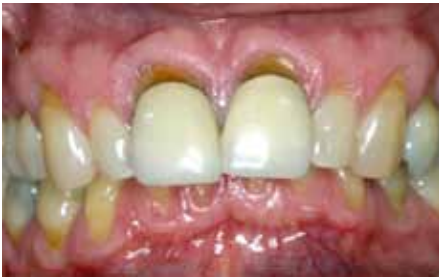

Fig. 19: Original situation 2004.

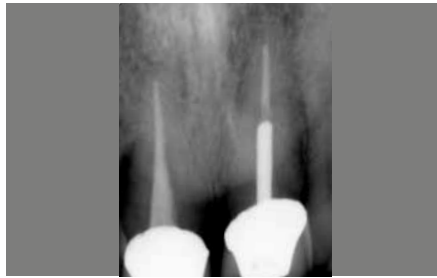

Fig. 20: Starting radiograph.

Here again was the situation at the start of therapy. A crisis situation with the fractured tooth was super-imposed on an unesthetic, deteriorating environment. The need for therapy for the immediate local problem needed to be blended with therapy to stabilize and improve the function and esthetics of the whole region.

## After

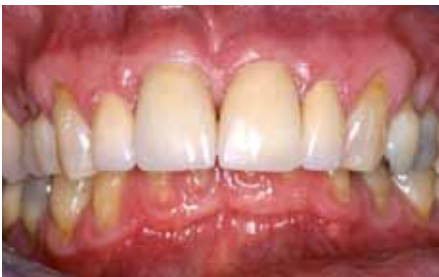

Fig. 21: Final situation 2005.

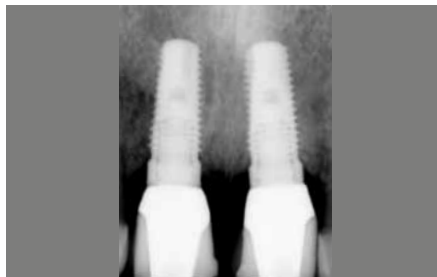

Fig. 22: Final radiograph 2005.

Therapy took nine months. On completion, the esthetics were improved and the situation was healthy and functional. All the way through treatment the patient had a fixed dentition. He was delighted with the result.

## CONCLUSION

The challenge of a case like this is to plan an even, smooth progression between stages. It's a matter of developing a vision of what one is trying to achieve, then working steadily and progressively to realize that vision. Along the way there are certain critical stages. In this case, there were three surgical options at the outset, but when the vertically fractured tooth was removed it was possible to move to immediate implant placement with concurrent augmentation of both hard and soft tissue complexes.

However, as is often the case, the initial implant stability was inadequate to support a provisional restoration, so it was useful to have a provisional bridge ready to put into place. This allowed healing to progress quite naturally, with no loading on the implants, bone graft or the soft tissue complexes.

When it came to the restorative phase, emergence profile development was critical. When the transgingival connection was made, the soft tissues overlying the healing cap were displaced rather than excised. An impression was taken at the same time, and the provisional restorations followed within a week. These started developing the desired emergence contours. The contours of the two teeth differed slightly. The implant replacing the left central incisor had been skewed slightly to the labial, so the contours of the provisional restoration were corrected to the lingual. Both provisionals were contoured against the lateral incisors and each other to develop the

desired papillae form. Instead of being blunted, and rounded, they became sharpened, elongated and «normal».

Moving forward to the final abutment and final restoration was then quite predictable, but still fraught with potential for error. These days, it's a relatively simple matter to copy-mill the contours of the final provisional, or at least those present in the sub-gingival region; and to reproduce those in the final abutment. However, five years ago when this case was done, it was necessary to alter stock components to achieve the desired results. In this case a 6.0 mm stock ceramic component was down-sized at the neck to fit a 5.0 mm post. This allowed a wider emergence, one that maintained the papillary contours achieved in the provisional. The final crowns on both the natural teeth and on the implant abutments were then able to blend and appear natural.

In every complex case, it's valuable to identify the stages of therapy that will be required. At the end of each stage, it's useful to stop and to re-evaluate the progress made. Slight alterations of therapy may be required and should enhance the final result. Changes provided towards the end of therapy should be refinements. Much depends on the biological response to therapy provided.

## RETROSPECTIVE REVIEW

It's always useful to review a case on completion. Could a better result have been achieved by other means? Could the case have been handled more efficiently and with fewer surgical interventions? How will the result survive over the long-term? Would one use the same procedures, apply the same principles and materials these days? Well, the five year evaluation shows the result to be quite stable. If anything the adjacent natural teeth have deteriorated slightly, but the implants, their restorations and the environment around them seems unchanged.

When this case was done, immediate implant therapy was not common. Neither was minimally invasive therapy, osseous augmentation around implants, "tunnelling" under flaps, flap advancement and soft tissue augmen-

tation at the time of implant placement. The rationale behind all these procedures is to stabilize the environment in an extraction socket and to prevent the inevitable hard and soft tissue loss which follows tooth loss. By thinking logically and by respecting the local biology it is possible to obtain predictable and stable long-term results.

The only changes to therapy that would be applied these days would be to use Promote® Plus implants instead of Promote®, to use Geistlich Bio-Oss® Collagen instead of Geistlich Bio-Oss® granules, to take a location impression at the time of implant placement and to place a custom zirconia Emergence on a K2244 Titanium Base Component at the time of second stage implant exposure. These would speed and improve healing and reduce the number of procedures.

### Before Photo

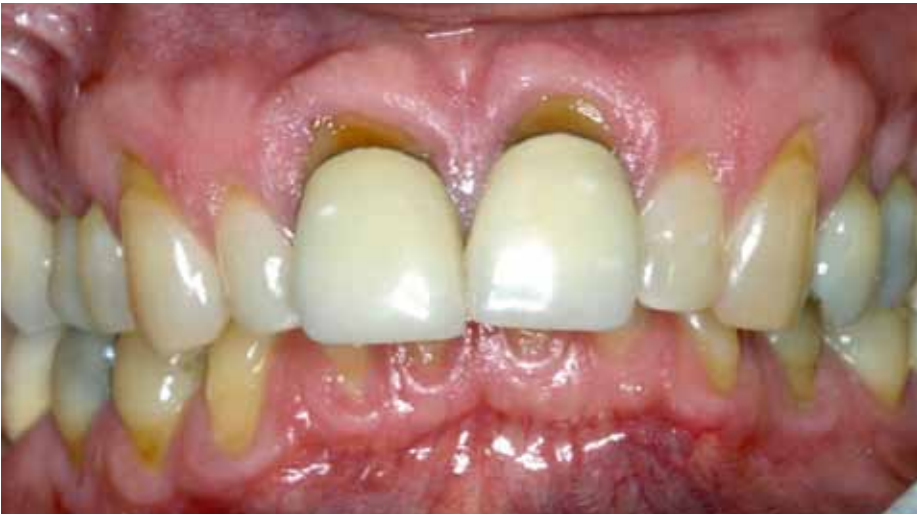

Fig. 23: Many different treatment plans could have been applied to this situation. It was necessary not only to replace the fractured tooth but also to stabilize the supporting structures. In the process it was desirable to enhance the esthetics.

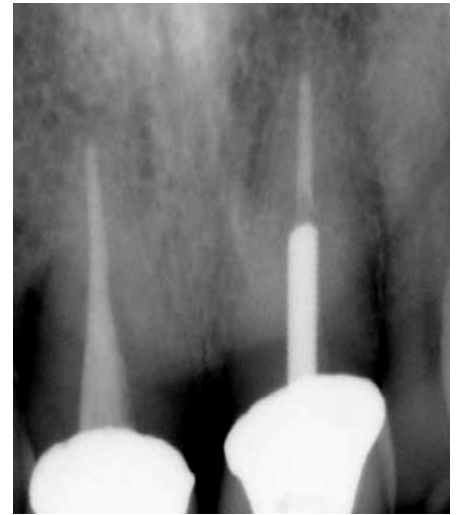

Fig. 24: Starting radiograph.

### After Photo

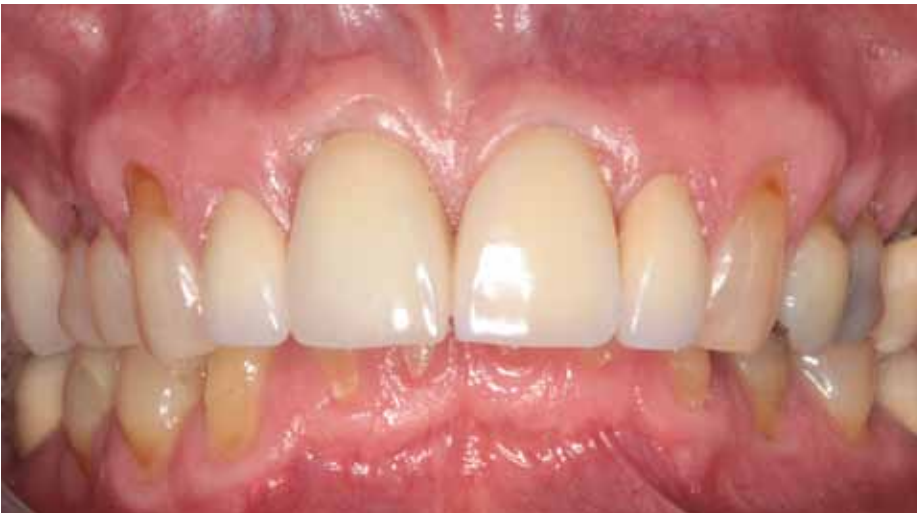

Fig. 25: At the five year recall, it can be seen that the goals of therapy were met and that the final situation is not only stable and functional but also esthetic.

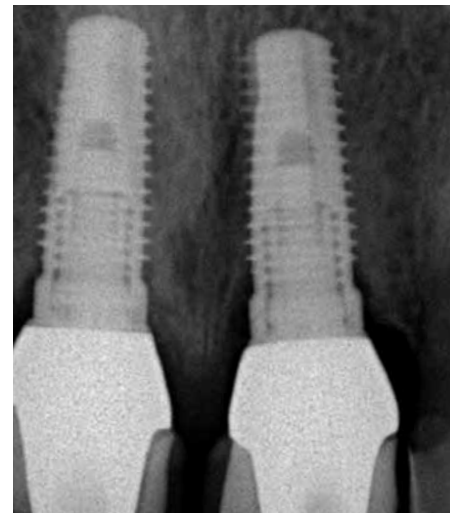


Fig. 26: Final radiograph 2010.



## **LITERATURE REFERENCES**

### **KRENNMAIR G, SEEMANN R, SCHMIDINGER S, EWERS R, PIEHSLINGER E**

Clinical outcome of root-shaped dental implants of various diameters: 5-year results. *Int J Oral Maxillofac Implants* **2010**; 25: 357-366.

### **ZAFIROPOULOS G, DELI G, BARTEE BK, HOFFMANN O**

Single tooth implant placement and loading in fresh and regenerated extraction sockets. 5 year results. A case series using two different implant designs. *J Periodontol.* **2010**; 81: 604-615.

### **ACKERMANN KL**

Extraction site management using a natural bone mineral containing collagen: rationale and retrospective case study. *Int J Periodontics Restorative Dent* **2010**; 29: 489-497.

## **CONTACT**

### **DR PETER HUNT**

266 So 21st Street, Philadelphia, PA 19103, USA

telephone: (215) 546-9813

e-mail: peter.hunt@DrPeterHunt.com

## **LABORATORY TECHNICIAN**

Boris Baranov CDT

**HEADQUARTERS**

CAMLOG Biotechnologies AG | Margarethenstrasse 38 | CH-4053 Basel | Switzerland  
Tel +41 61 565 41 00 | Fax +41 61 565 41 01 | [info@camlog.com](mailto:info@camlog.com) | [www.camlog.com](http://www.camlog.com)

**camlog**