

ANOTHER STRING TO OUR BOW

FOR PROSTHESES ON IMPLANTS: THE CAMLOG® VARIO SR ABUTMENT

a perfect fit™



Dr Eric Normand
Bordeaux, France

Eric Normand practices in Bordeaux, where he was born and began his studies. After his academic training in periodontology and implantology in Bordeaux, Paris, and New York, he taught these subjects at the University of Bordeaux 2. He has then devoted a full-time private practice exclusively to periodontology and implantology. He is still a lecturer at the Bordeaux Dental School and also provides continuing education instruction for scientific societies.

This clinical case presents the making of a straight maxillary bridge prosthesis over three implants, that is screw-retained on Vario SR abutments. The techniques are detailed step by step with practical advice.

IMPLANTS USED

Tooth	18	17	16	15	14	13	12	11	21	22	23	24	25	26	27	28
Impl. type			SL		SL	SL										
Impl. length			11.0		11.0	11.0										
Impl. Ø			4.3		4.3	3.8										
Impl. surface			PP		PP	PP										

Tooth	48	47	46	45	44	43	42	41	31	32	33	34	35	36	37	38
Impl. type																
Impl. length																
Impl. Ø																
Impl. surface																

Impl. type: ROOT-LINE (RL)/SCREW-LINE (SL) Impl. surface: Promote® (P)/Promote® Plus (PP)



PROSTHETICS

- removable
 - fixed
 - crown
 - cement-retained
 - screw-retained
 - partially edentulous
 - fully edentulous
 - other
-
- Universal abutment
 - Esthomic® abutment
 - Telescope abutment
 - Gold-plastic abutment
 - Ceramic abutment
 - CAD/CAM abutment on titanium base
 - Temporary abutment
 - Logfit® abutment
 - Locator® abutment
 - Bar abutment
 - Ball abutment
 - Vario SR abutment
 - other

INFORMATION ON PATIENT AND TREATMENT

The patient in very good health was an athlete almost 50 years old. He had been wearing a removable partial denture for more than five years to compensate for right maxillary tooth loss when he came to us for the first time. His request was clear, "I don't want to have an appliance anymore." His goal was more functional than cosmetic. The existing fixed prostheses covering the sectors adjacent to the missing teeth were fully satisfactory to him both cosmetically and functionally. The edentulous space was large, and a bridge over teeth would have led to short-term failure. The treatment plan was therefore straightforward: replace 13.14.15.16 with a fixed prosthesis over implants.

Clinical evaluation of the case showed a sufficient inter-arch space, good occlusion, and a significant amount of attached gingiva. The mucogingival junction was located far enough away from the middle of the crest. The mesiodistal distance was insufficient to replace the four missing teeth. We opted to make three teeth - one canine, one premolar, and one molar. The cone beam tomography showed significant residual bone volume, which gave us the best conditions for the implant insertion. It was therefore not necessary to perform preimplant surgery to augment hard tissue or soft tissue.

The following figures show the steps of the treatment.

Initial situation

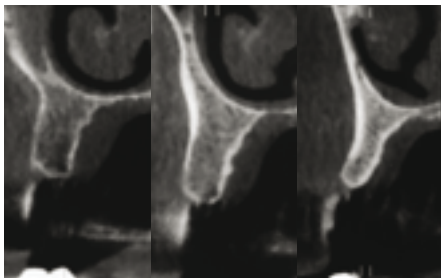


Fig. 1: Preoperative radiologic exam: tomography.

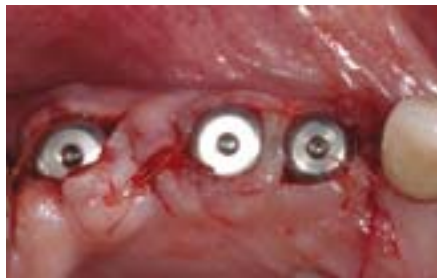

Fig. 2: Postoperative clinical view. The full-thickness flap with no incision for tension reduction was raised after placing the three implants (3.8 x 11 in position 13, 4.3 x 11 in 14 and 16) and their healing screws (wide body, 4 mm high). The small pedicle flaps, technique derived from Palacci, provided for closure of the edges without tension, forming the future papillae.

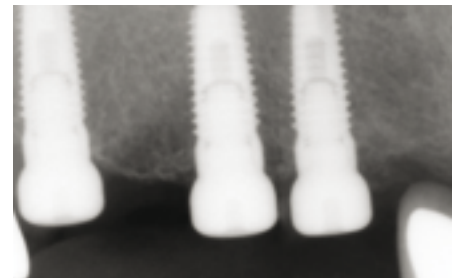


Fig. 3: Postoperative radiologic exam: periapical radiograph.

Prosthesis steps

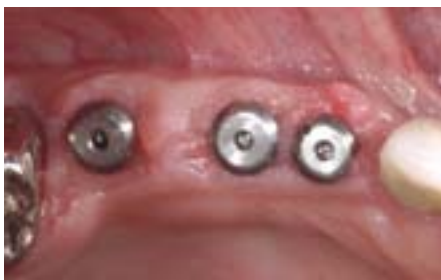

Fig. 4: Clinical view after healing: note the irregular wounds corrected later by gingivoplasty with a cautery knife.

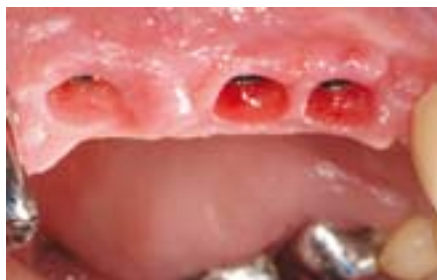

Fig. 5: Clinical view after eight weeks at the time of impression-taking.

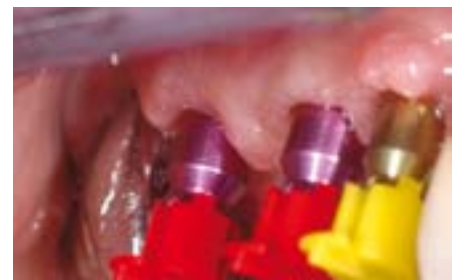

Fig. 6: Pop-in impression transfers in place. Note the use of closed-tray impression transfers, which are easier to use than open-tray transfers and are just as precise in the CAMLOG® Implant System when the implants show little angulation towards each other.

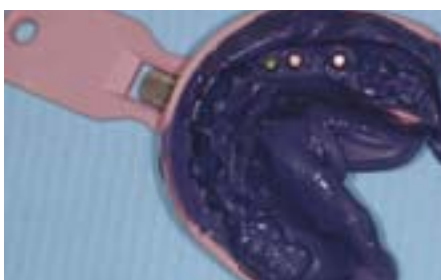

Fig. 7: Impression. Note that the colored caps have been removed.

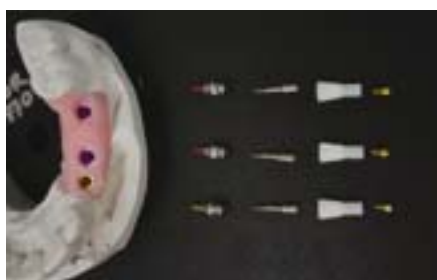

Fig. 8: Positive model with artificial gingiva and view of the parts used by the laboratory for making the bridge.

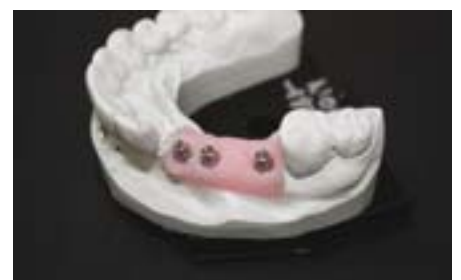

Fig. 9: Vario SR abutment in place. Because the implants show little divergence, straight abutments were used.

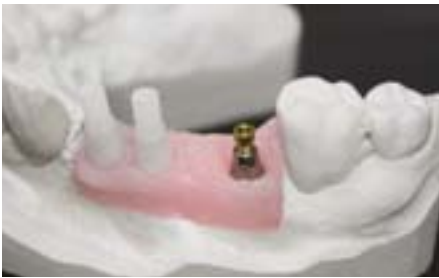

Fig. 10: Burn-out copings (no anti-rotation plane) in place.

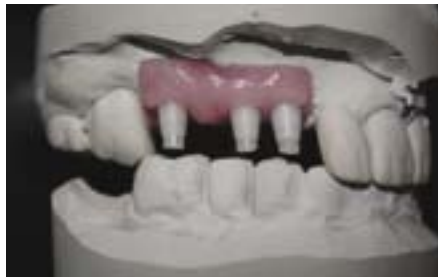

Fig. 11: Fitting of copings.

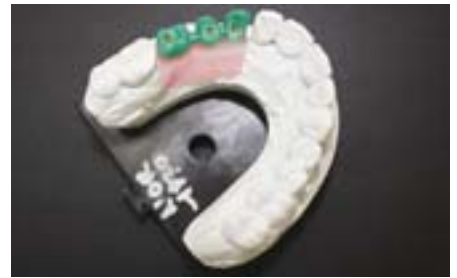

Fig. 12: Wax model.



Fig. 13: Cast framework.

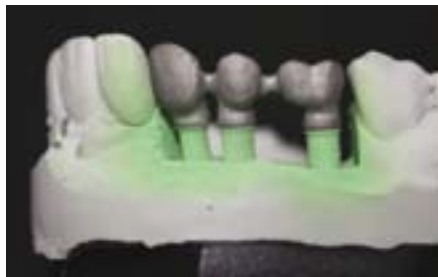


Fig. 14: Checking the framework on the model.



Fig. 15: Rough framework.

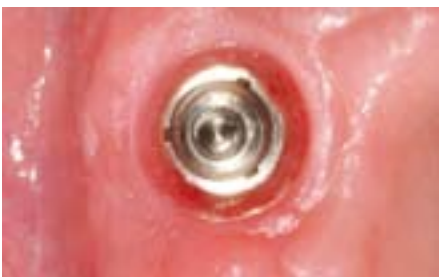

Fig. 16: View of the gingival wells formed by the healing caps.

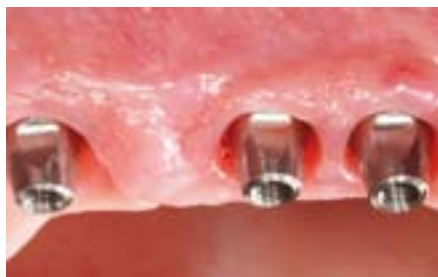

Fig. 17: Vario SR prosthetic abutments in place.

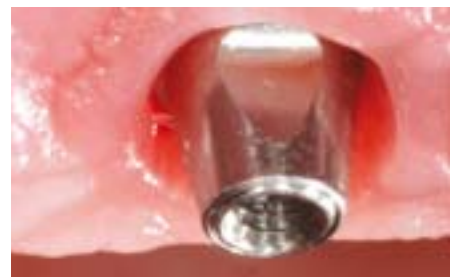

Fig. 18: Detail. Note the gingiva quality promoting overall long-term stability.

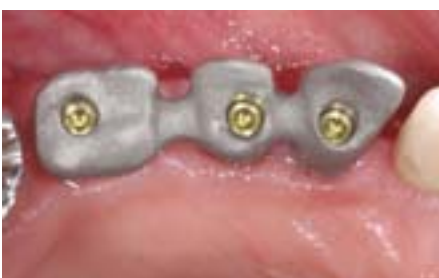

Fig. 19: Framework try-in.

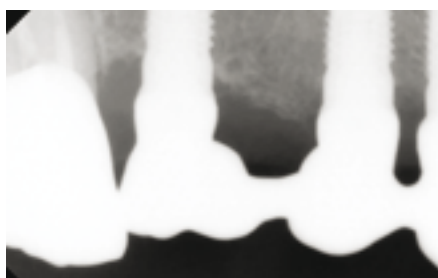


Fig. 20: X-ray check. Several x-rays were taken in between insertion of abutment screws to check for complete passivity of the framework.

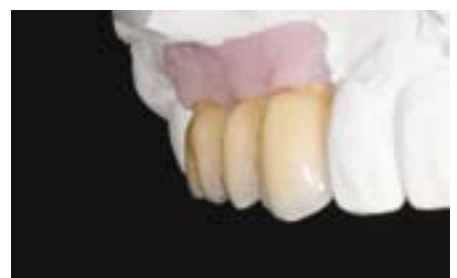

Fig. 21: Ceramic-veneered framework on the model.

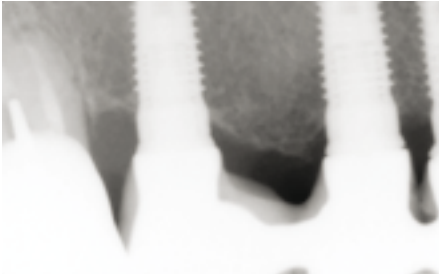


Fig. 22: X-ray check of the bridge during the try-in: note the slight gaps in the mesial implants. They were due to a contact point with 13 that was too tight.




Fig. 23: Another x-ray after adjustments: note the absence of a gap.

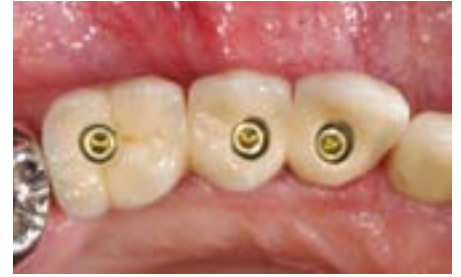

Fig. 24: Occlusal view of the bridge during the trial. The abutment screws were then tightened to 20 Ncm, and the prosthetic screws were tightened to 15 Ncm.

Final situation

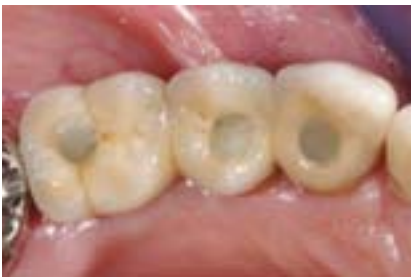

Fig. 25: Occlusal view after the occlusal access wells were filled with a cotton pellet and an addition of composite. Note the irregular non-homogeneous appearance, which was accentuated by the flash picture. As clinicians, we find this appearance non-cosmetic, but it has not bothered the patient in the least.

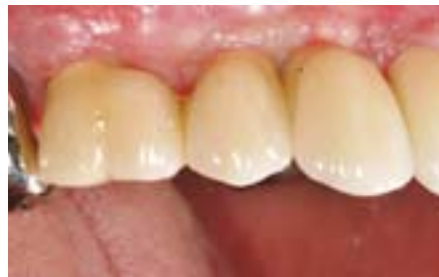

Fig. 26: Buccal view three months after insertion of the prosthesis.

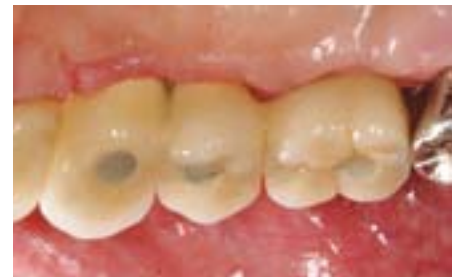

Fig. 27: Palatine view three months after insertion of the prosthesis.

COMMENTS

The one-stage surgical procedure accounts for more than 90% of our activity and enables us to take advantage of a longer period of mucosal healing at the same time as bone healing in cases where burying the implant during the osseointegration phase can be avoided and there is good primary stability, which is easily obtained with the SCREW-LINE implant shape.

The significant amount of attached gingiva and bone volume in this case allowed us to perform surgery with **minimal** detachment of soft tissues. With raising of the flaps, we do not have to work blindly in the bone crest, and we can manage the inter-implant gingiva volume optimally.

It is important to adjust the temporary removable denture properly during the osseointegration phase and to warn the patient, because any contact between the temporary prosthesis and the healing screw can result in loss of the underlying implant.

The impression with the pop-in system shows precision that is similar to a pickup impression insofar as the implants are not divergent. We use these transfers in over 99% of cases.

Initial post-surgery situation

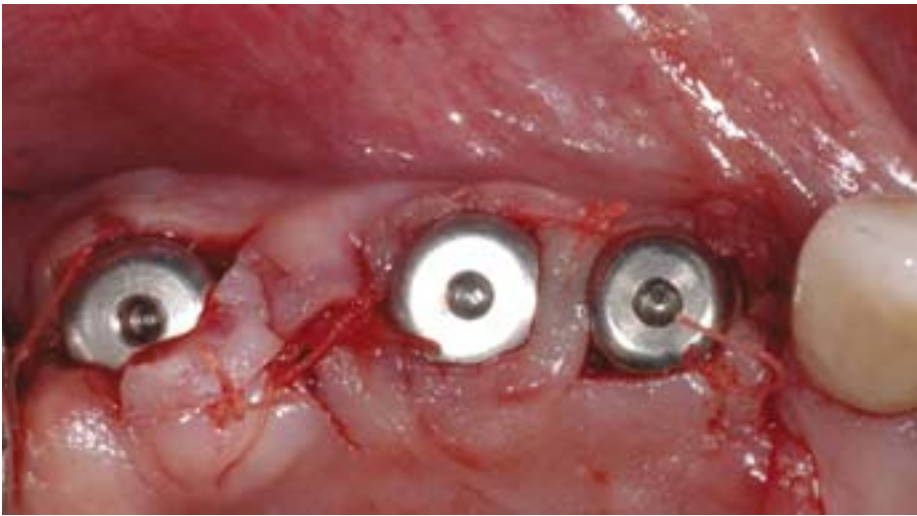


Fig. 28 View immediately after surgery.

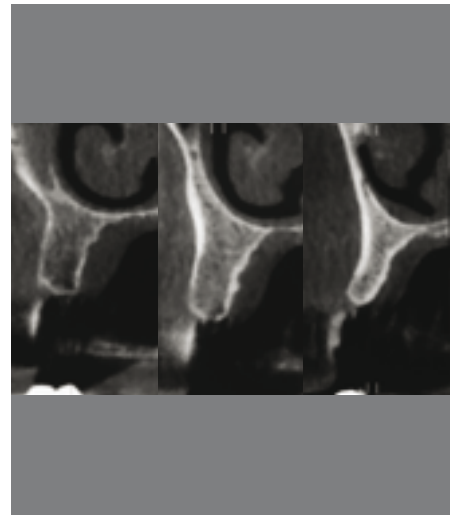


Fig. 29: Preoperative tomography.

Final situation

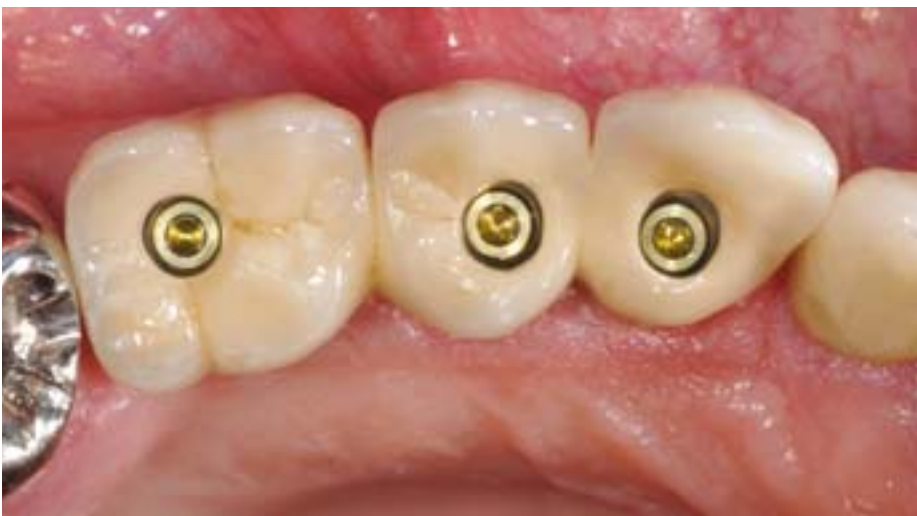

Fig. 30: Final view before composite is placed in the screw access wells.

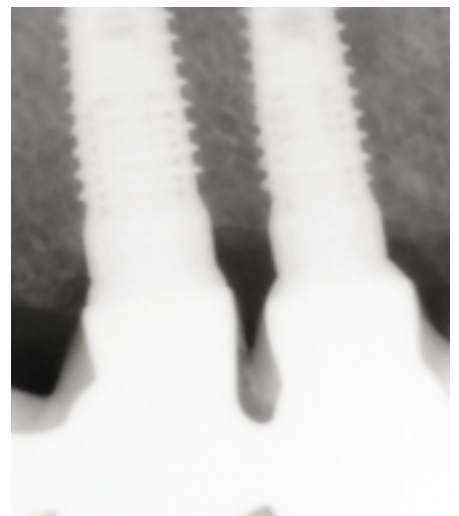

Fig. 31 Final x-ray.

CONCLUSIONS

The Vario SR abutments allow us to make a screw-retained prosthesis on implants in a straightforward and precise manner.

In addition, time is saved with no concessions on precision or quality by using clinical protocols that are more straightforward and rational than "traditional" protocols: one-stage surgery, limited non-invasive flaps, impression with pop-in transfers, easy repositioning of abutments, use of only one screwdriver throughout the treatment, and splinted crowns.

The screw-retained prosthesis also avoids any risk of residual cement around the implant neck.

REFERENCES

SEMPER W, HEBERER S, MEHRHOF J, SCHINK T, NELSON K

Effects of repeated manual disassembly and reassembly on the positional stability of various implant-abutment complexes: an experimental study. *Int J Oral Maxillofac Implants.* **2010** Jan-Feb;25(1):86-94.

PALACCI P, NOWZARI H

Soft tissue enhancement around dental implants. *Periodontol 2000.* **2008**;47:113-32.

MICHALAKIS KX, HIRAYAMA H, GAREFIS PD

Cement-retained versus screw-retained implant restorations: a critical review. *Int J Oral Maxillofac Implants.* **2003** Sep-Oct;18(5):719-28.

REFERENCES FOR PARTS AND MATERIALS USED

CAMLOG® SCREW-LINE implants

Vario SR straight prosthetic abutments

Burn-out sleeves for bridges

Ceramic-metal prosthesis

Moteur Acteon/Satelec implant center 2, Mérignac, France

CONTACT

Dr Eric Normand

124 rue Croix de Seguey

33000 Bordeaux

France

Email: dr.eric.normand@gmail.com

RADIOLOGY

Dr Laurent Hauret, Bordeaux

DENTAL TECHNICIANS

Gilles Nauzes and Jérôme Bellamy

Laboratoire Cristal, Bordeaux

published in LE FIL DENTAIRE - October 2010

HEADQUARTERS

CAMLOG Biotechnologies AG | Margarethenstrasse 38 | CH-4053 Basel | Switzerland
Tel +41 61 565 41 00 | Fax +41 61 565 41 01 | info@camlog.com | www.camlog.com

camlog