

Preservation of crestal bone level at non-submerged CAMLOG titanium implants with standard or platform switched configuration

The influence of platform switching and non-platform switching on crestal bone level changes over six months was evaluated in an experimental animal study using a new non-submerged titanium implant type (CAMLOG, K-Series). Histological data demonstrated successful integration of the implants into hard and soft tissue as well as stable crestal bone levels in both modalities.

Background

Titanium dental implants become firmly incorporated into living bone tissue by forming a bond between implant surface and bone. This bony anchorage is a stable structure usually maintained for a lifetime (Lekholm et al., 2006; Astrand et al., 2008). Another essential tissue component of successfully integrated dental implants is the peri-implant soft tissue. Attached to the implant surface it forms a functional barrier between oral cavity and alveolar bone to protect the bone from potential infiltrating contaminants of the oral environment (McKinney et al., 1984). However crestal alveolar bone at two-piece implants is typically remodelled during the first year of loading resulting in marginal bone loss that may extend to 2 mm (Albrektsson et al., 1986; Smith and Zarb, 1989; Jung et al., 1996). Factors associated with this bone resorption process include inflammation at the implant-abutment interface (Ericsson et al., 1995; Herman et al., 2001), formation of a normal biologic width (Berglundh and Lindhe, 1996), dis- and reconnections of the abutment compromising the mucosal barrier (Abrahamsson et al., 1997), as well as apparently aspects of the implant design such as the macro-design (Zechner et al., 2004; Shin et al., 2006) and the position of the smooth-rough surface border (Hermann et al., 2000).

Based on this knowledge the Research and Development Department of CAMLOG Biotechnologies AG has systematically developed and tested design changes of the CAMLOG implants in order to improve the formation and maintenance of the structure of the soft and hard tissue attachment.

Reduced machined surface segment

First, the machined surface segment of the SCREW-LINE implant neck was significantly reduced to the Promote® plus design, i.e. a reduction from 2.0 mm

to 0.4 mm. The changes resulting from moving the smooth-rough surface border were analyzed in dogs for a healing period of 3 months (Schwarz et al., 2008). The data demonstrated that the new surface design efficiently reduced crestal bone changes. It could be concluded that when a native thick gingiva was available, an approximately 1 mm higher bony integration level of the implant could be accomplished without the marginal epithelium reaching the micro-structured surface (Becker et al., 2006).

Platform switching

The second approach to minimize crestal bone changes was to use a modified implant-abutment configuration. This alternative design contains a reduced diameter of the abutment relative to the diameter of the implant platform (called platform switching), an optimized connection with reduced cam-grooves in height and an




Fig. 1 Schematic illustration of CAMLOG® SCREW-LINE Promote® plus (K-Series) implants with standard (control, left) and non matching (platform switching, right) wide body healing abutments

improved guiding. Through the horizontal platform the distance between the implant-abutment interface and the alveolar crest is increased and hence the hypothesized influence of the inflammatory cell infiltrate on bone resorption is decreased. Another advantage of the platform switching design could be the gain of surface area at the platform of the implant. This surface gain may facilitate the soft tissue to attach and to reduce bone resorption since less surface area is now required at the implant neck (Lazzara and Porter, 2006). Furthermore there is some preliminary evidence that this specific implant-abutment configuration decreases stress translation to the crestal bone-implant interface (Maeda et al., 2007; Schrotenboer et al., 2008) and thus reduces bone loss.

Two animal studies were performed to investigate the principle of platform switching with CAMLOG implants.

The first experimental dog study indicated that a circumferential horizontal platform of 0.5 mm prevents the apical downgrowth of the barrier epithelium over an observation period of 28 days and therefore slightly better preserved the crestal alveolar bone at the implant (Becker et al., 2007).

The second platform switching study in dogs was conducted over a period of 6 months to obtain long term data on the maintenance of soft and hard tissue at the implant (Becker et al., submitted). The second generation of CAMLOG® SCREW-LINE Promote® plus implants (K-Series; \varnothing 3.8 mm; L 11 mm, Fig. 1) were inserted according to the standard surgical protocol approximately 0.4 mm above bone level after mucosal incision with mucoperiosteal flaps in the posterior region of the mandibles (Fig. 2). At least 1 mm residual thickness of the alveolar bone crest at both buccal and lingual aspects of each implant site was preserved. Wide-body matching healing abutments (\varnothing 3.8 mm, H 4 mm, standard configuration) and non-matching (\varnothing 3.2 mm, H 4 mm, platform switching configuration) randomly assigned in a split-mouth design were connected and served either as control or test implants with a circumferential horizontal platform of 0.3 mm, respectively.

The histological examination after 4 weeks of healing revealed that at both test and control implants a mature woven bone was formed spanning the gap between the adjacent alveolar bone and the implant surface. Considering the initial insertion depth, first appearance of crestal bone changes could be observed in both groups without reaching statistical significance.

Fig. 2 Surgical procedure (pictures by courtesy of J. Becker and F. Schwarz)

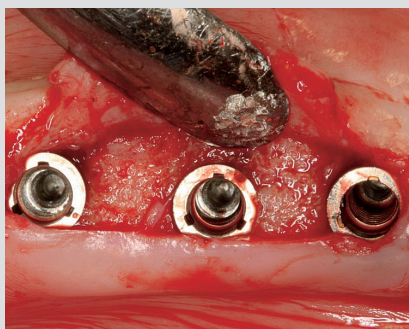


Fig. 2a
Implants (K-Series) inserted 0.4 mm supracrestal according to the standard surgical protocol

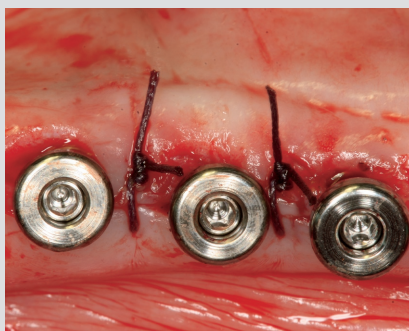

Fig. 2c
Implants with healing abutments were left to heal in a transgingival position



Fig. 2b
Inserted implant covered with a nonmatching healing abutment (platform switching)

Fig. 3 Histological specimens in the lingual (left) and buccal (right) direction after 6 months of healing (Masson Goldner stain) showing stable crestal bone levels at implants with matching and non-matching healing abutments (pictures by courtesy of J. Becker and F. Schwarz)



Fig. 3a
Implant with
standard healing
abutment (control)



Fig. 3b
Implant with non-
matching healing
abutment (platform
switching)

While at 8 weeks the wound healing was characterized mainly by parallel fibered bone, at 12 weeks the deposition was predominated by mature lamellar bone. Bone loss tended to be slightly increased for the control implants compared to the platform switched implants as was measured by the distance between implant shoulder and crestal bone level (IS-BC). At 12 weeks, the difference of IS-BC between control and test implants was at the buccal aspect 0.5 mm and at the lingual aspect 0.4 mm ($p < 0.05$; unpaired t-test), respectively. A similar result could be observed at 24 weeks when remodelling at the alveolar crestal bone seemed to decline (Fig 3). The difference of IS-BC between both groups was settling down to approximately 0.3 mm.

Conclusion

The data of this animal study demonstrate that the new CAMLOG implants (K-Series) when placed 0.4 mm supracrestally in their standard or in their platform switching configuration successfully integrate into hard and soft tissue. Both bone remodelling as well as soft tissue adaption appear to be minimal at the implant-abutment interface during the first 8 weeks of osseointegration and considerably less pronounced after 6 months resulting in a stable crestal bone level. The platform switching implants tended to yield better results regarding maintenance of the bone level. Further studies are ongoing.

References

- Abrahamsson I, Berglundh T, Lindhe J. The mucosal barrier following abutment dis/reconnection. An experimental study in dogs. *J Clin Periodontol.* 1997 Aug; 24 (8):568-72.
- Albrektsson T, Zarb G, Worthington P, Eriksson AR. The long-term efficacy of currently used dental implants: a review and proposed criteria of success. *Int J Oral Maxillofac Implants.* 1986 Summer; 1 (1):11-25.
- Astrand P, Ahlqvist J, Nilson H. Implant treatment of patients with edentulous jaws: a 20-year follow-up. *Clin Implant Dent Relat Res.* 2008 10 (4):207-217.
- Becker J, Schwarz F, Kirsch A. Verbesserung der marginalen Knochenadaption durch das neue Promote® plus Design. *Logo* 2006;6:15-17. (CAMLOG Partner Magazine)
- Becker J, Ferrari D, Herten M, Kirsch A, Schaer A, Schwarz F. Influence of platform switching on crestal bone changes at non-submerged titanium implants: a histomorphometrical study in dogs. *J Clin Periodontol.* 2007 Dec; 34 (12):1089-96.
- Becker J, Ferrari D, Mihatovic I, Schaer A, Schwarz F. Stability of crestal bone level at platform switched non-submerged titanium implants. A histomorphometrical study in dogs. Submitted.
- Berglundh T, Lindhe J. Dimension of the periimplant mucosa. Biological width revisited. *J Clin Periodontol.* 1996 Oct; 23 (10):971-3.
- Ericsson I, Persson LG, Berglundh T, Marinello CP, Lindhe J, Klinge B. Different types of inflammatory reactions in peri-implant soft tissues. *J Clin Periodontol.* 1995 Mar;22(3):255-61.
- Hermann JS, Buser D, Schenk RK, Cochran DL. Crestal bone changes around titanium implants. A histometric evaluation of unloaded non-submerged and submerged implants in the canine mandible. *J Periodontol.* 2000 Sep; 71 (9):1412-24
- Hermann JS, Schoolfield JD, Schenk RK, Buser D, Cochran DL. Influence of the size of the microgap on crestal bone changes around titanium implants. A histometric evaluation of unloaded non-submerged implants in the canine mandible. *J Periodontol.* 2001 Oct; 72 (10):1372-83.
- Jung YC, Han CH, Lee KW. A 1-year radiographic evaluation of marginal bone around dental implants. *Int J Oral Maxillofac Surg.* 1996; 65:33-39.
- Lazzara RJ, Porter SS. Platform switching: a new concept in implant dentistry for controlling postrestorative crestal bone levels. *Int J Periodontics Restorative Dent.* 2006 Feb; 26 (1):9-17.
- Lekholm U, Gröndahl K, Jemt T. Outcome of oral implant treatment in partially edentulous jaws followed 20 years in clinical function. *Clin Implant Dent Relat Res.* 2006;8(4):178-186.
- Maeda Y, Miura J, Taki I, Sogo M. Biomechanical analysis on platform switching: is there any biomechanical rationale? *Clin Oral Implants Res.* 2007 Oct; 18 (5):581-4.
- McKinney RV Jr, Steflik DE, Koth DL. Per, peri, or trans? A concept for improved dental implant terminology. *J Prosthet Dent.* 1984 Aug; 52 (2):267-9.
- Schrotenboer J, Tsao YP, Kinariwala V, Wang HL. Effect of microthreads and platform switching on crestal bone stress levels: a finite element analysis. *J Periodontol.* 2008 Nov;79(11):2166-72.
- Schwarz F, Herten M, Bieling K, Becker J. Crestal bone changes at nonsubmerged implants (Camlog) with different machined collar lengths: a histomorphometric pilot study in dogs. *Int J Oral Maxillofac Implants.* 2008 Mar-Apr; 23 (2):335-42.
- Shin YK, Han CH, Heo SJ, Kim S, Chun HJ. Radiographic evaluation of marginal bone level around implants with different neck designs after 1 year. *Int J Oral Maxillofac Surg.* 2006; 62; 567-572.
- Smith DE, Zarb GA. Criteria for success of osseointegrated endosseous implants. *J Prosthet Dent.* 1989 Nov;62(5):567-72.
- Zechner W, Trinkl N, Watzak G, Busenlechner D, Tepper G, Haas R, Watzek G. Radiologic follow-up of peri-implant bone loss around machine-surfaced and rough-surfaced interforaminal implants in the mandible functionally loaded for 3 to 7 years. *Int J Oral Maxillofac Implants.* 2004 Mar-Apr; 19 (2):216-21.

CAMLOG Biotechnologies AG
Margarethenstrasse 38
CH 4053 Basel
Tel. +41 (0) 61/565 41 00
Fax. +41 (0) 61/565 41 01
info@camlog.com
www.camlog.com

camlog