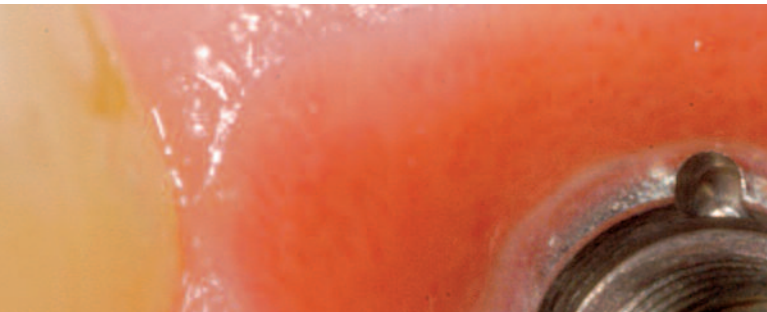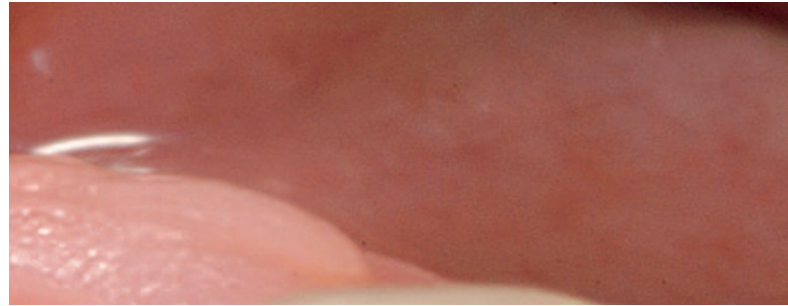

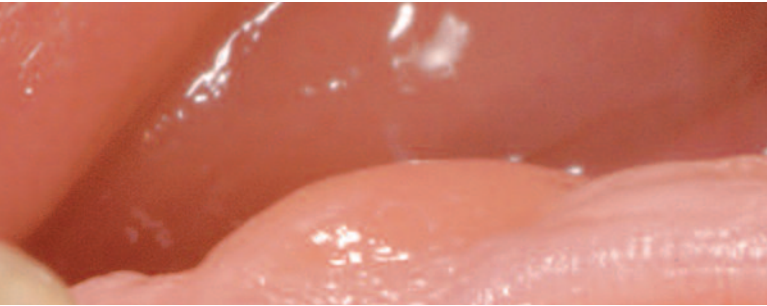


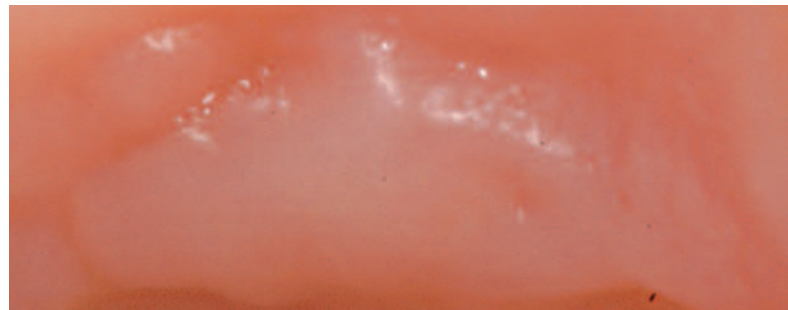
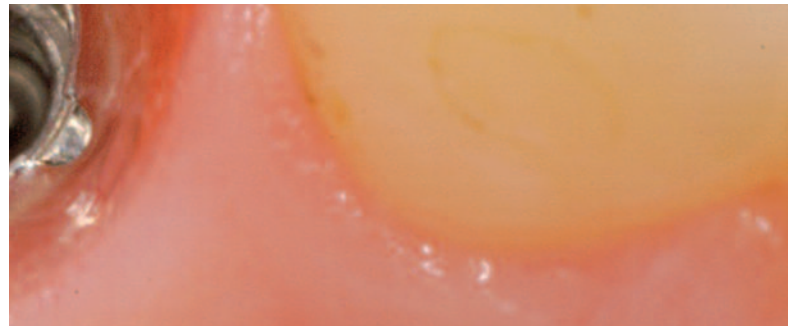
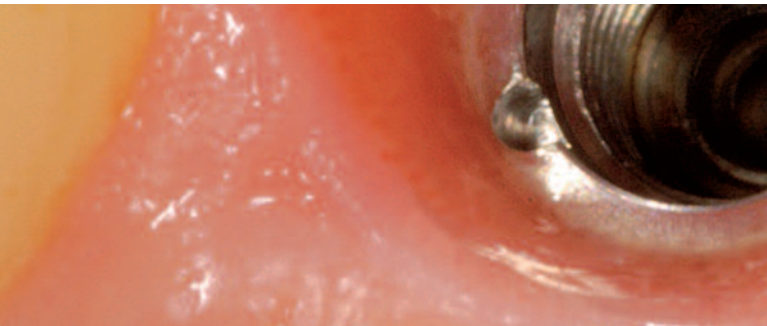# EDI Journal

European Journal for  
Dental Implantologists



## Augmentation Techniques – the Basis of Aesthetic Success in Implant Dentistry

A Contribution by  
Dr. Claudio Cacaci, Munich, Germany



Kindly offered by:

**camlog**  
BIOTECHNOLOGIES

# Augmentation Techniques – the Basis of Aesthetic Success in Implant Dentistry

Dr. Claudio Cacaci, Munich, Germany

Situations of tooth loss are commonly accompanied by a reduced volume of all associated structures, notably of the surrounding bone and soft tissue. The use of guided tissue regeneration (GTR, a more specific term being guided bone regeneration, GBR) in dental implantology was initially confined to minor defects. Non-resorbable membranes were used exclusively at that time. More recently, however, treatment objectives and guidelines have dramatically changed. Implant placement is today guided exclusively by aesthetic, prosthetic and biofunctional criteria. Missing bone volume is restored by surgical means. Thus dental implantology has essentially turned into a prosthetic discipline with a surgical component. But why?

Surgical techniques to improve bone quality and quantity at implant sites are today well established, and the clinical steps involved are based on solid ground. Experienced surgeons using precise incisions, atraumatic instruments, appropriate tissue management and correct augmentation techniques are able to convert inadequate bone areas to stable implant sites in a safe and predictable manner.

An established technique to improve bone quality is to use osteotomes for bone condensation, particularly in the spongy areas of the maxillary posterior segments. Gentle condensation of the spongy bone compartment will increase the rate of bone apposition on the implant surface, thereby contributing to the primary stability of the implant.

The bone quantity of planned implant sites can be improved by various surgical approaches depending on the type, size and location of the bone defect. The following techniques need to be distinguished.

Horizontal ridge expansion

- Bone spreading
- Bone splitting
- Onlay techniques using particles
- Onlay techniques using blocks

Vertical ridge expansion:

- Sinus floor elevation
- Alveolar ridge distraction

The present article will focus on the various techniques used to expand the horizontal bone dimension. Special emphasis will be placed on the role of autologous bone harvesting and on appropriate treatment decisions in the presence of various defect configurations.

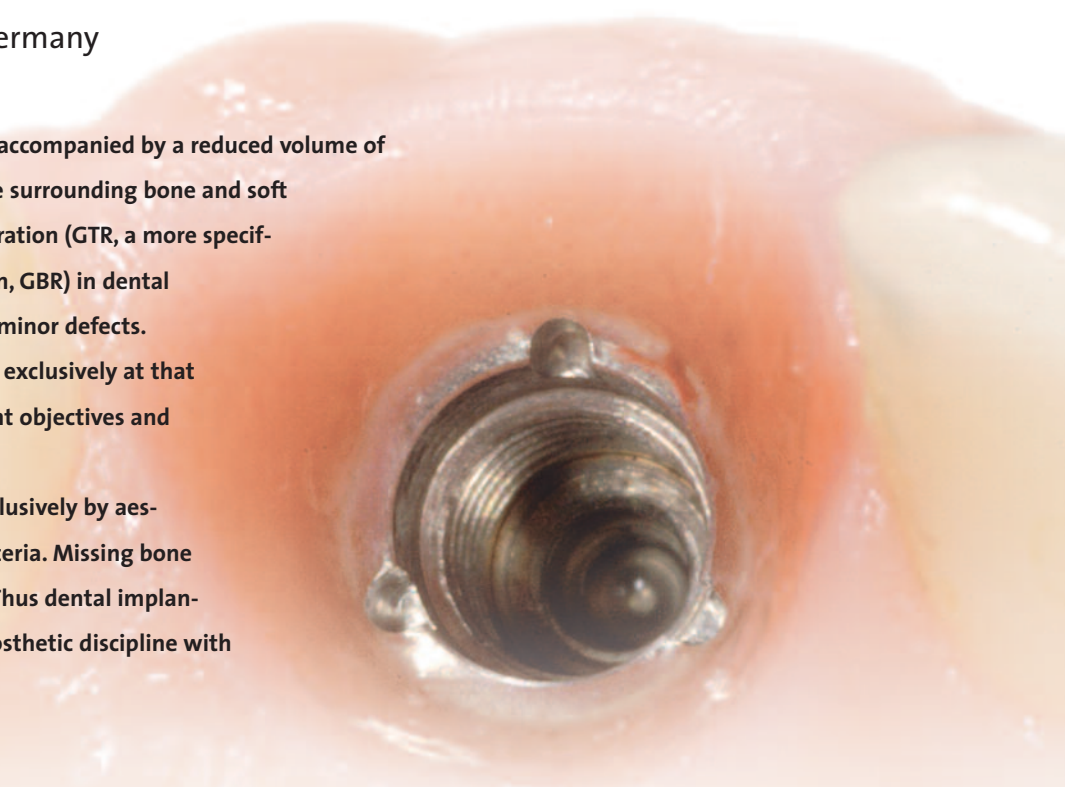


Fig. SP1  
Horizontally  
reduced bone  
due to agenesis  
of the later-  
al incisors.

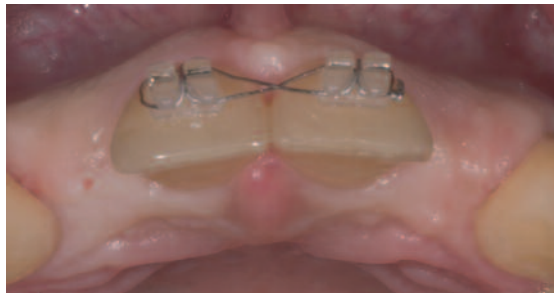

Fig. SP2  
Bone spread-  
ing with a flat  
chisel.

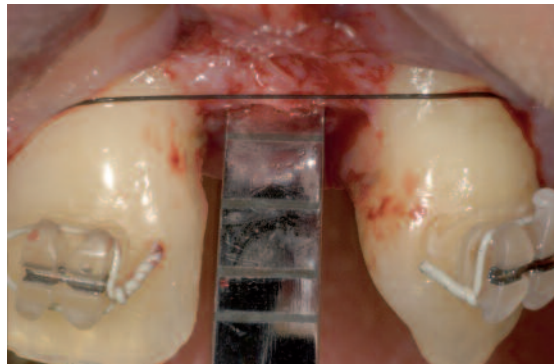


Fig. SP3  
Bone spread-  
ing with an  
osteotome.

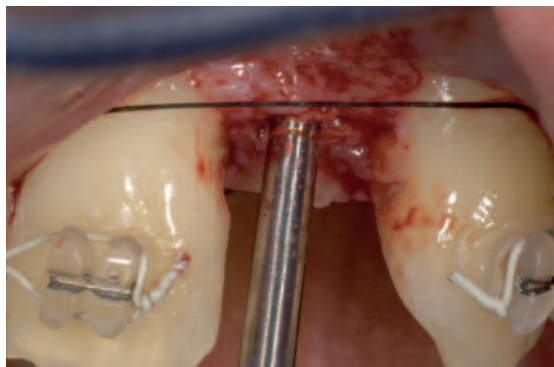


Fig. SP4  
Correct  
implant posi-  
tion 1,5 mm  
away from the  
adjacent root  
with slightly  
palatal angu-  
lation.

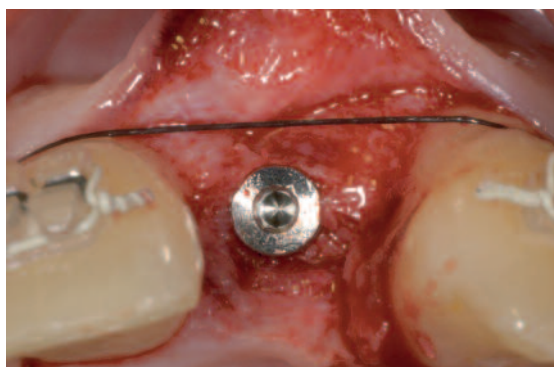
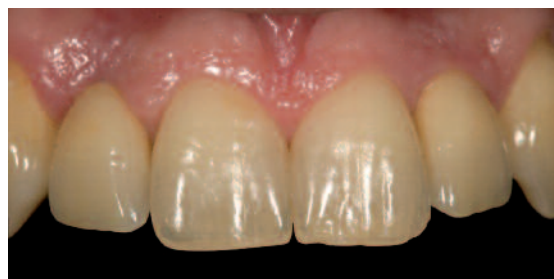
Fig. SP5  
Treatment  
outcome.



## Classification of defects

Numerous classification systems for bone defects have been proposed. In our practice, we favour the classification by *Ferher* and *Schärer* (1999).

## Class o/I situations

Classes o and I do not constitute a bone deficit. Class o indicates that the alveolar ridge is well shaped without showing any kind of defect. Class I refers to situations preceded by atraumatic tooth removal but not involving a bone defect.

### *Agenesis*

Tooth agenesis has always been a major indication for implant treatment. Tooth loss is commonly associated with bone defects of varying severity. This is particularly true in the aesthetic zone, coinciding with the anterior segment of the maxilla (Classes o and I). At sites of congenitally missing lateral incisors, for example, the horizontal bone dimension is usually inadequate. In this situation, an adequate implant bed can be created by the combined use of bone splitting and spreading (Figures SP1–SP5).

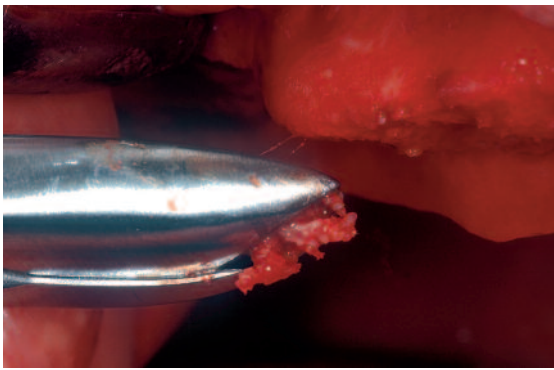
A combination of bone spreading and bone splitting may be sufficient to prepare the alveolar ridge for accepting dental implants. To ensure a successful aesthetic outcome, it is essential that an accurate implant position is secured despite the horizontally reduced bone.

## Class II defects

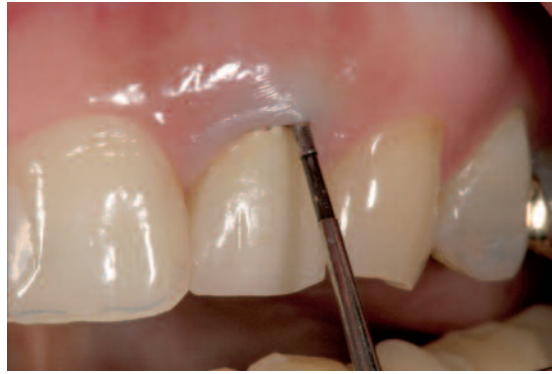Class II indicates that a facial bone deficit of 1–3 mm is present. A variety of factors can give rise to hard-tissue deficits after tooth loss. A common cause is the occurrence of subacute inflammatory processes in endodontically treated teeth with vertical root fractures (Figures E1–E4).

When the defect was exposed six weeks after tooth extraction, a well-circumscribed three-dimensional bone defect became evident both in the vestibular portion of the bone lamella and circularly in the area of the implant shoulder.

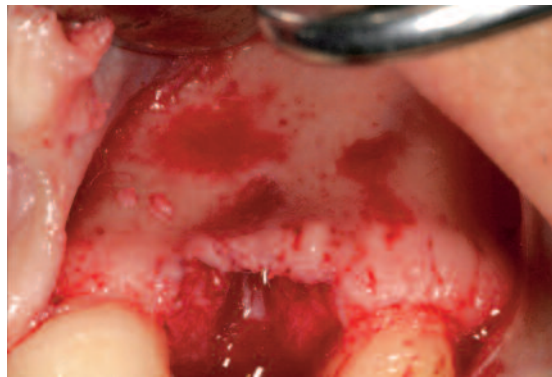
Sufficient amounts of autologous bone to augment minor defects can be readily harvested from the tuberosity, preferably with a chisel or Luer rongeur (Figure T2).



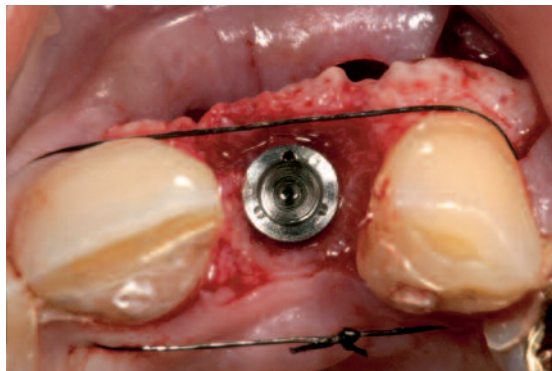
*Fig. T2 Harvesting of autologous bone from the tuberosity with a Luer rongeur has a low degree of invasiveness and yields enough material to augment minor defects.*



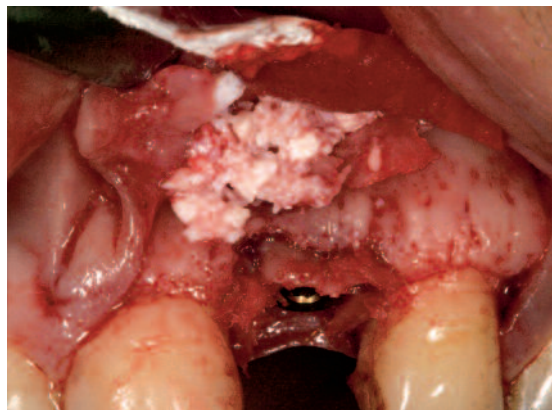
*Fig. E1 Longitudinal root fracture, subacute symptoms, buccal bone deficit on probing.*



*Fig. E2 Facial bone defect.*



*Fig. E3 Bone defect at the level of the implant shoulder (vertical/horizontal).*



*Fig. E4 Defect treatment with autologous bone graft, bone substitute (Bio-Oss) and resorbable collagen membrane (BioGide).*

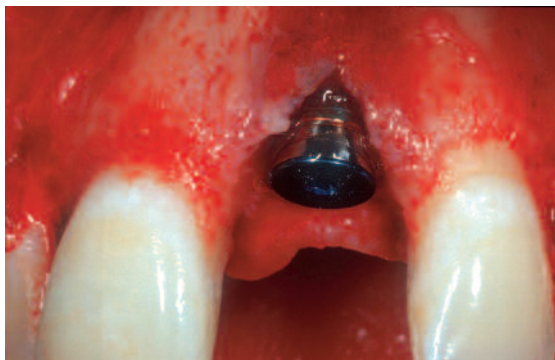

Fig. D1 Bone deficit following implant placement.

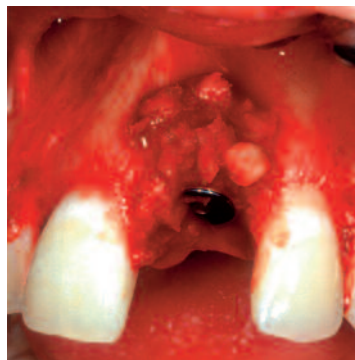

Fig. D2 Defect filling with autologous bone. Facial overcontouring is only required if an adequate buccal thickness of the bone cover (at least 3 mm) has to be established.

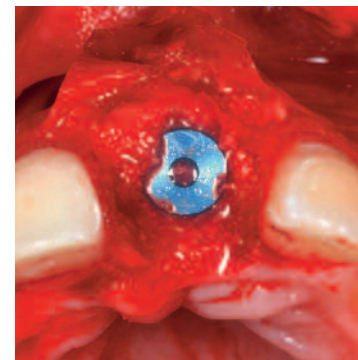


Abb. D3: Defektkonturierung mit Gemisch aus autologer Spongiosa und Bio-Oss (Geistlich), Defektdeckung mit resorbierbarer Membran (BioGide, Geistlich)

Fig. D4 A trephine cutter is used to harvest bone from the ascending ramus. The spongy bone in that region can be carefully extracted with a sharp scoop.

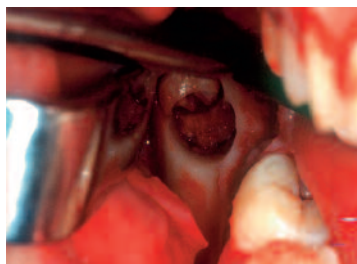


Fig. KW2 Autologous bone material after harvesting, stored in autologous blood.

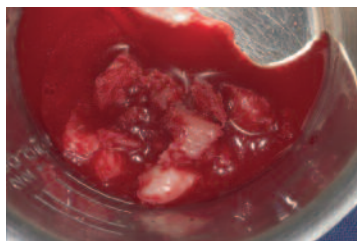


Fig. D5 Temporary resin abutment for gingival shaping.

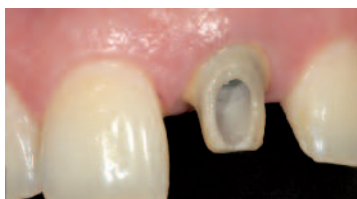

Fig. D6 Zirconium abutment.

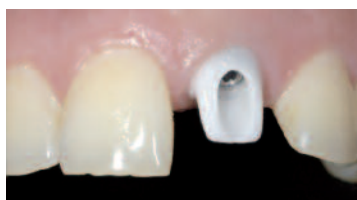
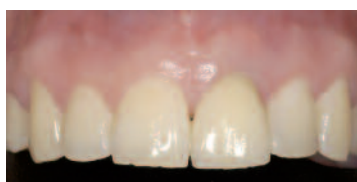
Fig. D7 All-ceramic restoration.



### Class III defects

Class III indicates that a buccal bone deficit of  $> 3$  mm is present. With appropriate surgical techniques, these situations can still be treated in a single-step procedure. In other words, bone augmentation and implant placement are performed in the same session. Care must be exercised in patient selection, as this approach has been reported to involve increased complication rates. In the following example, an undiagnosed root fracture preceded by anterior trauma gave rise to a class III defect after two years of subchronic inflammation. There were more than 3 mm of buccal lamella missing (Figures D1–D3).

In the presence of major bone defects, the mandibular angle is an appropriate harvesting site, which, if anatomical conditions are favourable, will yield sufficient amounts of bone to the action of using cutters, oscillating saws, diamond discs or trephine burs (Figure D4).

A trephine cutter is used to harvest bone from the ascending ramus. The spongy bone in that region can be carefully extracted with a sharp scoop (Figure KW2).

Aesthetic components used in the restorative phase included temporary resin abutments (PE resin) to shape the gingiva and definitive zirconium abutments to support the all-ceramic restoration (Figures D5–D7).

## Class IV/V defects

Classes IV and V refer to bone areas not capable of accommodating implants in their current state because the available bone volume at the planned site is inadequate. Class IV is defined by the absence of the buccal lamella; class V is additionally characterized by vertical bone loss. Situations of this type are primarily encountered in the anterior segment after trauma, multiple apical resection or extensive inflammation. Ridges too narrow for implant placement are also observed in situations of agenesis or teeth having been lost a long time back. According to investigations by Buser and Grunder, a fixture whose vestibular surface is only covered by 1 mm of bone cannot possibly be stable. This finding is consistent with our own experience and is particularly true of the anterior segment. For stable long-term results, a bone thickness of at least 3–4 mm is required. Otherwise the peri-implant tissue will sooner or later recede, thereby causing aesthetic deficits.

Class IV and V defects require a step-by-step approach, the primary objective being to augment the bony defect. Very often, this has to be followed by additional procedures to optimize the soft-tissue structures. Preparing the ground for a tooth-like emergence profile by conditioning the peri-implant soft tissue is a major concern in the restorative phase.

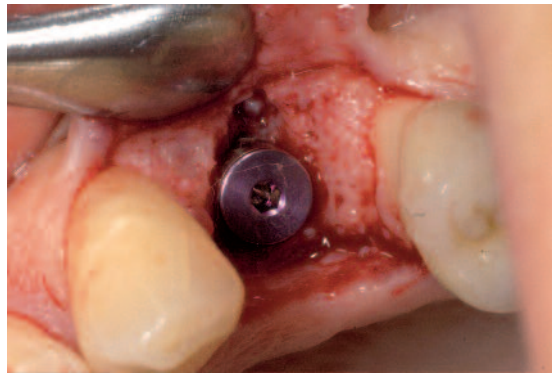
## Enossal bone harvesting

The following bone regions can be eligible for harvesting:

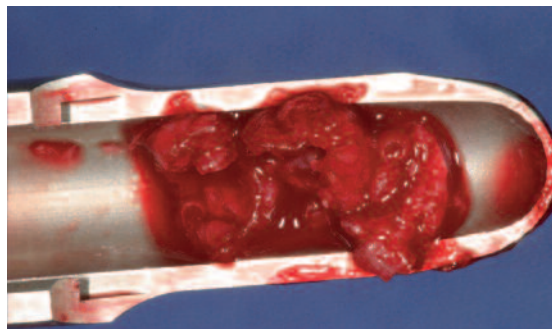
- Peri-implant environment (drilling chips, bone scraper)
- Tuberosity
- Mandibular angle, retromolar mandibular segment
- Symphysis

Which of these regions is appropriate to use will depend on the following criteria:

- Required bone volume
- Anatomical conditions at the harvesting site
- Bone quality at the harvesting site
- Postoperative trauma by bone harvesting



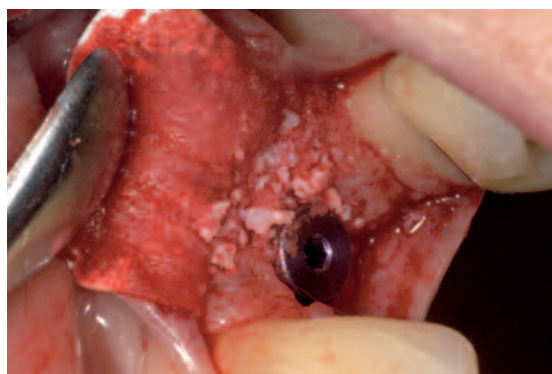
*Fig. A1  
Minor bony dehiscence on the buccal aspect.*



*Fig. A2  
Bone chips harvested with a scraper from the peri-implant environment.*

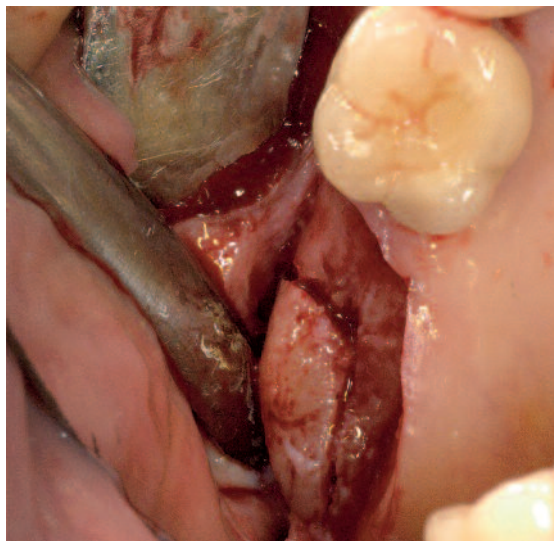


*Fig. A3  
Bone chips collected during implant bed preparation.*

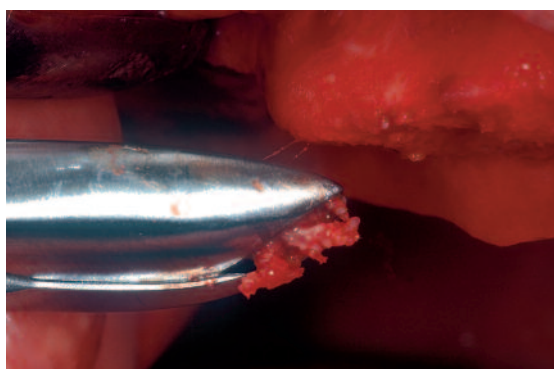


*Fig. A4  
Defect filling with harvested bone. Autologous bone is introduced directly into the defect, xenologous material (Bio-Oss, Geistlich) is added to protect against resorption and for contouring. The defect is then covered with a resorbable membrane (BioGide, Geistlich).*

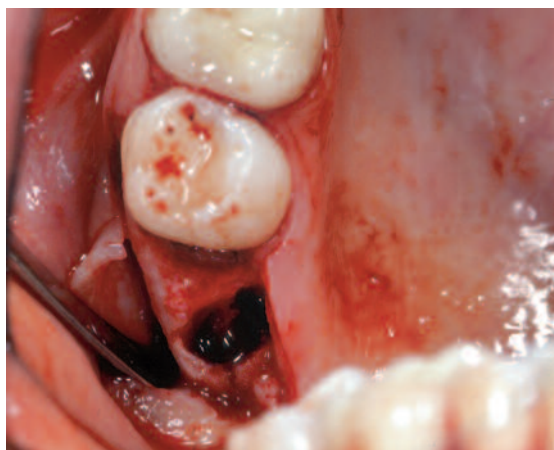*Fig. T1  
Bone harvest-  
ing from the  
tuberosity  
with a chisel.  
The palatal  
wall is spared.*



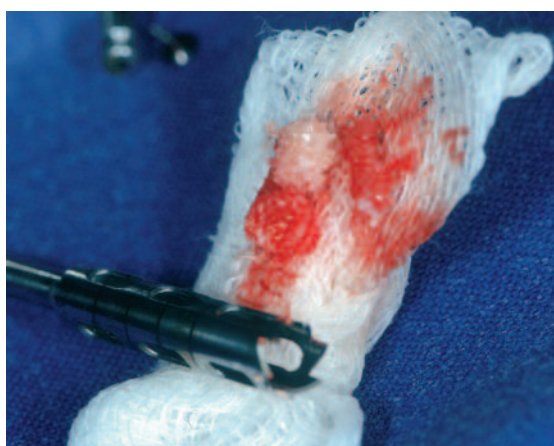*Fig. T2  
Bone harvest-  
ing from the  
tuberosity  
with a Luer  
rongeur.*



*Fig. T3  
Bone harvest-  
ing from the  
tuberosity  
with a small  
trephine.*



*Fig. T4  
Autologous  
material har-  
vested from  
the tuberosity  
with a  
trephine  
cutter.*



## Bone harvesting from the peri-implant environment

To augment minor bone defects, it is frequently sufficient to harvest autologous bone from the peri-implant environment (Figures A1–A4). Autologous grafting material should be placed such that direct contact with the implant surface is established. To avoid premature resorption of the augmented area, an additional layer of resorbable xenogenous material (e.g. Bio-Oss, Geistlich) is applied and covered with a membrane. Using a resorbable collagen membrane (BioGide, Geistlich) for coverage will prevent dislocation of the augmented bone during the healing phase and guard against soft-tissue ingrowth into the defect (Figure A4).

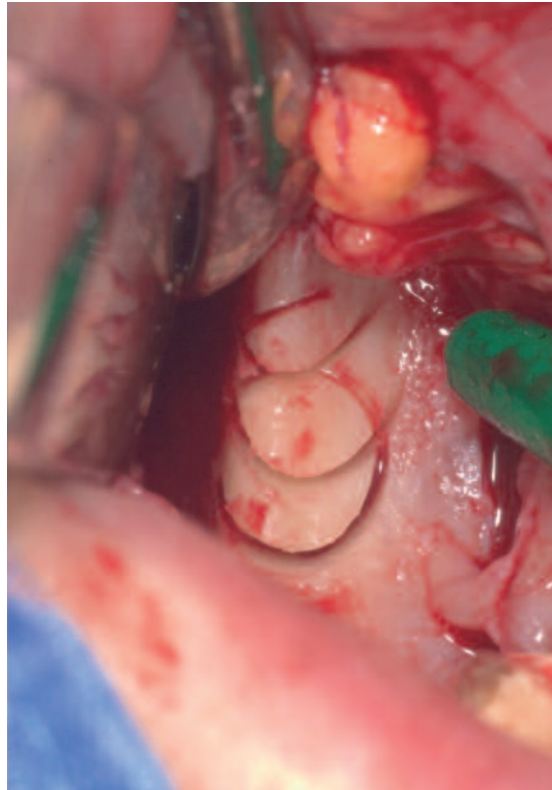
## Bone harvesting from the tuberosity region

The surgical procedure of harvesting autologous bone from the tuberosity region is simple and involves only minor postoperative trauma. Note, however, that the deposition of fat in the tuberosity region may be significant depending on the patient's age and individual anatomy, which will reduce the osteogenic properties of the harvested bone. The material is collected using a chisel and small trephine burs or simply with a Luer rongeur. Care must be taken to spare the palatal wall of the tuberosity to avoid structural alterations in that region (Figures T1–T4).

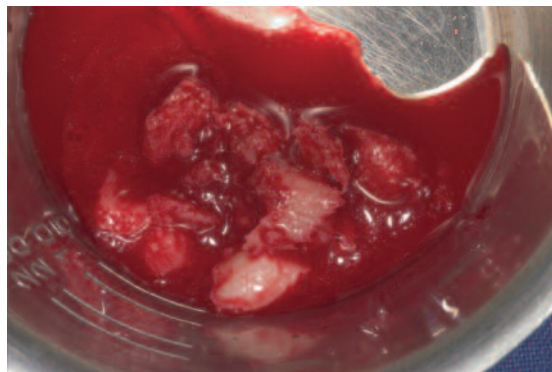
## Bone harvesting from the mandibular angle

The retromolar mandibular segment (mandibular angle) is normally a good place for harvesting major amounts of bone. The bone volume available for harvesting can be greatly reduced, however, in older patients exhibiting atrophic processes or if the alveolar nerve is located close to the surface. Therefore, anatomical structures that are worth protecting should be thoroughly analyzed by appropriate radiographic techniques, and the surgical approach for bone harvesting should be adjusted to the individual situation. Generally speaking, however, the mandibular angle is the preferred site for enossal bone harvesting in the hands of experienced surgeons. In terms of postoperative symptoms, bone harvesting in that area resembles an osteotomy of a moderately impacted third molar. The rate of postoperative complications is low. The bone is harvested using a block osteotomy or a trephine. Since protection of the nerve structures (inferior alveolar nerve, lingual nerve) is mandatory, the surgeon has to know where these are located (Figures KW1–KW4). Special retractors should be used to protect the soft tissue. The harvested bone is introduced to the augmentation site either directly as a block transplant, or the bone is first crushed and then applied as a particulate graft. For structural integrity and to avoid intraoperative or postoperative fractures, care must be taken to maintain an adequate dimension of the lingual lamella.

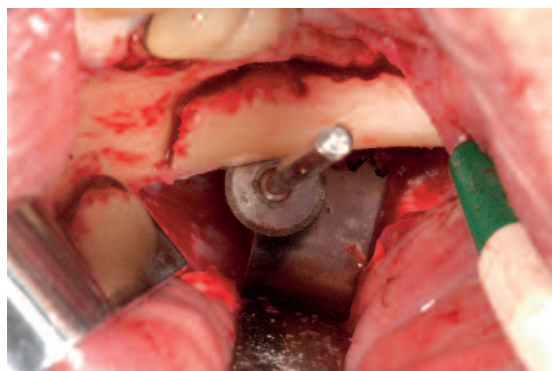
The bone wound should be subjected to haemostasis after harvesting, using either bone wax or a haemostatic collagen fleece to fill the defect (Figures FL1–FL3). It is not necessary to use a bone substitute.



*Fig. KW1  
Bone harvesting from the ascending ramus with a trephine cutter.*



*Fig. KW2  
Spongy and cortical bone harvested from the mandibular angle with a trephine.*



*Fig. KW3  
Block harvesting from the mandibular angle using thin bone cutters and a diamond disk. Special wound retractor according to Cacaci (underneath diamond disk; Stoma Instrumente).*



Fig. KW4  
Bone block  
harvested  
from the  
mandibular  
angle.

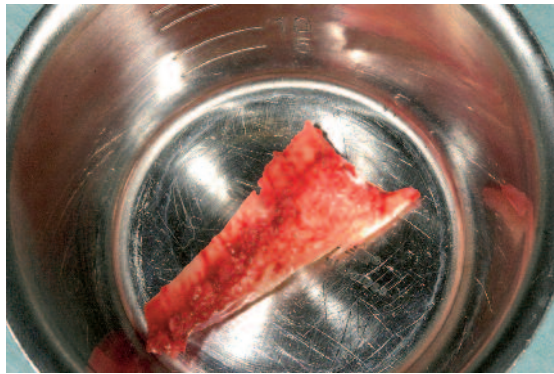

Fig. FL1  
Block harvest-  
ing from the  
mandibular  
angle.

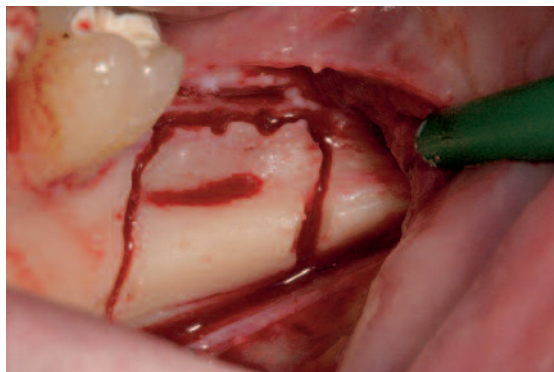


Fig. FL2  
Wound dress-  
ing with  
equine colla-  
gen fleece  
(Tissufleece,  
Baxter).

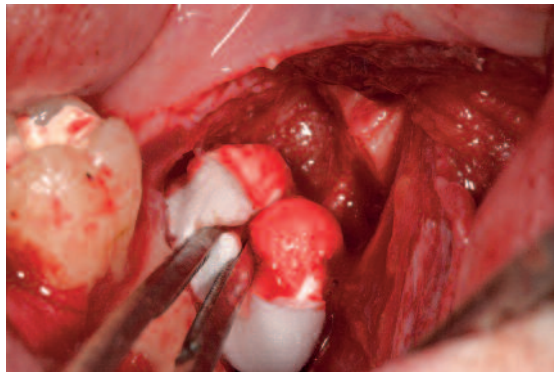
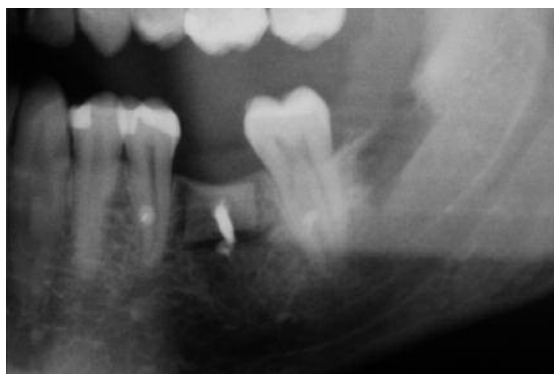

Fig. FL3  
Postoperative  
radiograph of  
a bone block  
harvested  
from the retro-  
molar  
mandibular  
segment, fixat-  
ed with a Cor-  
ticofix screw  
(CAMLOG) at  
the first molar  
position.



## Bone harvesting from the symphysis

The symphyseal region is readily accessible, thus being an apparent candidate for bone harvesting. On the other hand, the rate of postoperative complications has been shown to be particularly high with this approach. These eventualities need to be discussed with the patient in detail. Frequent complications include:

- Desensitization of the mandibular anterior teeth
- Devitalization of the mandibular anterior teeth
- Alteration of facial contours (pendulous chin)
- Scarring
- Wound dehiscence

It takes surgical prudence and plenty of experience to avoid these complications. The surgical instrument has to steer clear of the root tips to avoid damaging these structures. Temporary or permanent desensitization of the anterior teeth is a routine outcome and therefore needs to be discussed with the patient. Engaging the mandibular border with the instrument carries a risk of contour alterations and has to be strictly avoided. Furthermore, care must be taken to accurately prepare the soft-tissue structures (mucosa, subepithelial connective tissue, muscles, periosteum) layer by layer. Failure to do so can lead to local wound dehiscence, unpleasant scarring or even contour alterations (Figure SY1). Depending on the individual anatomical situation, large amounts of bone can be harvested from the symphyseal region.

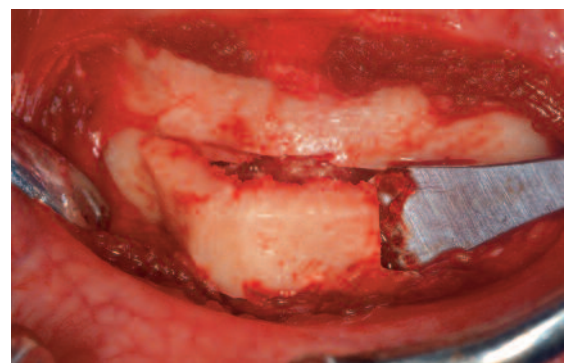
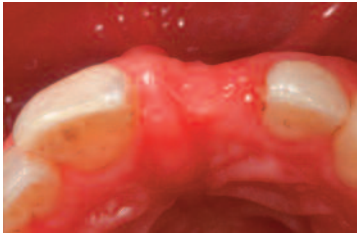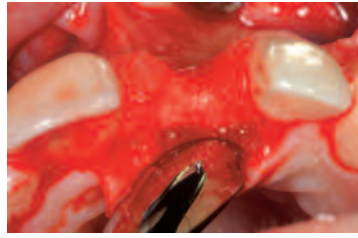


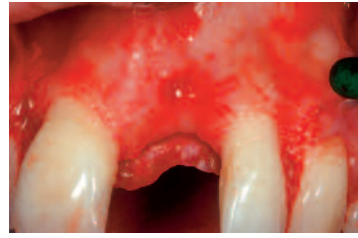
Figure SY1: Block harvesting from the symphyseal region. The anterior roots and mandibular border must be strictly avoided. Care must be taken to accurately prepare the soft-tissue cover layer by layer, exposing the site and followed by wound dressing.



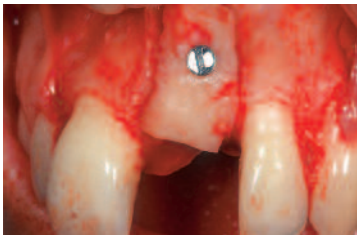
*Fig. B1 Juvenile traumatic tooth loss.*



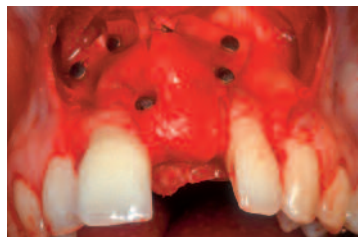*Fig. B2 Horizontal bone loss extending facially over the entire root length.*



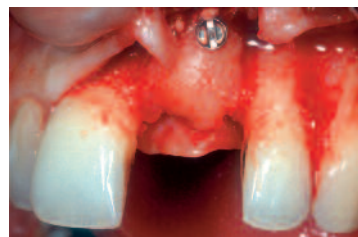*Fig. B3 Combined three-dimensional defect with a vertical component (class V).*



*Fig. B4 The bone block is effectively immobilized in the defect area by the Corticofix screw. Surface contact with the native bone is required for the transferred bone block to be reliably pervaded. Micromovements need to be ruled out.*



*Fig. B5 Membrane coverage using a mucosa-friendly semipermeable collagen membrane (BioGide, Geistlich). The membrane is fixated to protect the augmented bone against resorption.*



*Fig. B6 There are virtually no signs of resorption after 5 months of healing. The Corticofix screw has been removed prior to implantation.*

## Management of Class V defects

The primary goal in the presence of extensive three-dimensional defects is to reconstruct the missing bone structure, preferably by block osteotomy and autologous block grafting. Soft-tissue management is particularly important in this situation, as the augmented bone must be reliably covered with soft tissue during the healing phase to ensure a successful outcome. We routinely use fixated blocks of spongy cortical bone, combined with resorbable membranes to protect the augmentation material against resorption. This approach involves a low rate of complications in the presence of appropriate soft-tissue management, the use of microinstruments, and thanks to the good biocompatibility of the resorbable collagen membrane.

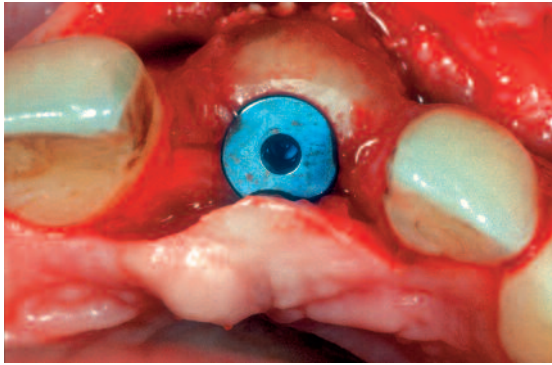
Augmentation is performed by onlay grafting of a bone block. A special osteosynthesis screw (Corticofix-System, CAMLOG) is used for fixation. This traction screw will ensure that the bone block is completely immobilized by exerting pressure on the bony bed (Figure B4).

Then a mixture of autologous spongy bone and Bio-Oss (Geistlich) is placed on the bone block for defect contouring. Finally, the material is covered with a resorbable membrane (BioGide, Geistlich) to protect the augmented site from uncontrolled resorption (Figure B5).

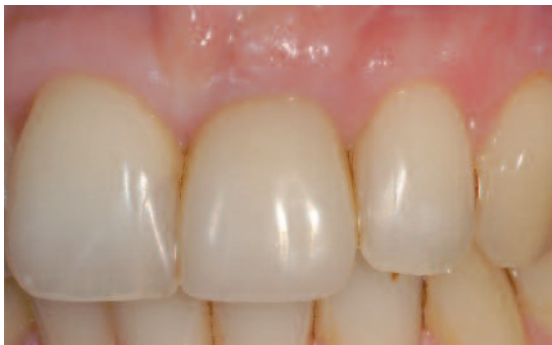After a healing period of five months, the site is once again surgically exposed, showing virtually no signs of resorption. This is followed by implant placement in conjunction with soft-tissue augmentation. After another healing period of four months, the implant is uncovered and fitted with a temporary restoration for soft-tissue conditioning (Figures B6–B9).

Finally, a CAMLOG zirconium abutment and an all-ceramic restoration are inserted to optimize the aesthetic outcome of treatment (Figure B10–B11).

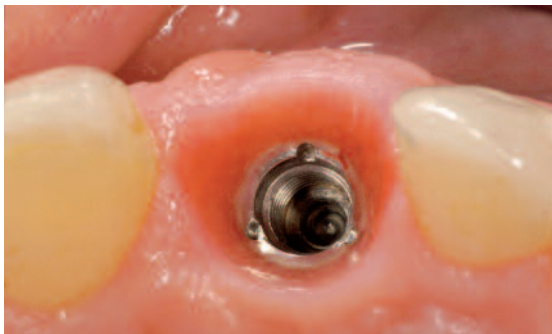*Fig. B7  
CAMLOG  
implant  
(diameter 5  
mm) in place.  
Adequate size  
of the buccal  
lamella follow-  
ing augmenta-  
tion.*



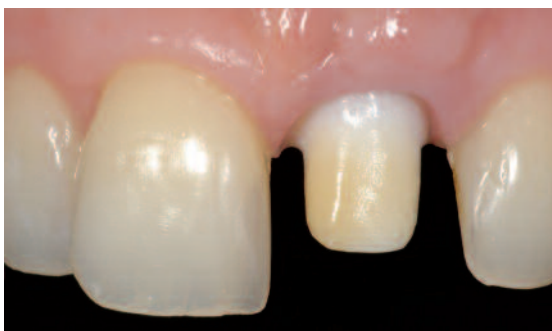*Fig. B8  
Restorative  
phase after  
placement  
of a tempo-  
rary restora-  
tion for  
gingival  
shaping.*



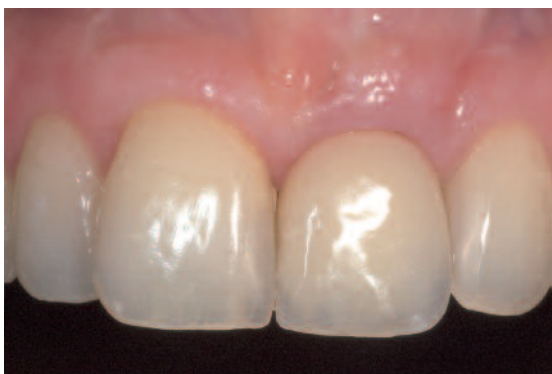*Fig. B9  
Implant sur-  
rounded by  
healthy peri-  
implant soft  
tissue of  
adequate  
thickness.*



*Fig. B10  
Modified zirco-  
nia abutment  
in place.*



*Fig. B11  
All-ceramic  
restoration.  
The excess soft  
tissue on the  
facial surface  
is going to be  
removed after  
2 years at the  
earliest.*



## Summary

Patients' aesthetic demands have become the main criterion by which to judge the achievements of modern dental implantology. Consequently, implant positioning is dictated by restorative considerations rather than by the traditional criteria of bone quantity and morphology. Techniques of guided bone regeneration have significantly expanded the spectrum of indications, and restorative treatment steps are today facilitated by advanced implant hardware.


Two distinct strategies are used to address bone defects in the aesthetic zone: single-step procedures and staged approaches. Single-step procedure means that bone augmentation and implant placement are performed in a single session. This approach should remain confined to two-wall bone defects (classes I and II). Single-wall defects should be addressed in a staged procedure. Approaching the problem step by step will offer maximum control of the hard and soft tissue structures involved. The first step is to augment the bone using block grafts. The second step is to place the implants and perform soft-tissue adjustments if necessary. The restorative phase is initiated by delivering temporary restorations that will shape the emergence profile.

Careful patient selection is recommended in all situations, and patients with large defects should be duly informed about existing limitations. (References available from the author.) ■

## VITA:

### Claudio Cacaci, Dr. med. dent.

1986–1991	Medical school in Munich, Germany
1991–1993	Clinic and Polyclinic for Dental and Maxillofacial Surgery in Munich, Germany
1994–1996	Polyclinic for Dental Surgery and Implantology, Frankfurt, Germany
1995	Authorized specialist in oral surgery
1996	Assistant Medical Director at the Polyclinic for Dental Surgery and Implantology, Frankfurt, Germany
1997	Private practice together with Dr. Jan Hajto in Munich, Germany



NEW IMPLANTS, NEW ABUTMENTS  
**LIBERTY OF CHOICE**  
NATURALLY FROM **CAMLOG**

Reliable implants, patented Tube-in-Tube™ connection, and from now on as an option: platform switching. Camlog offers more. More information: [www.camlog.com](http://www.camlog.com)

a perfect fit®

**camlog**